



Biology, diagnosis and treatment of *Malassezia* dermatitis in dogs and cats

Clinical Consensus Guidelines of the World Association for Veterinary Dermatology

Ross Bond* , Daniel O. Morris†, Jacques Guillot‡, Emmanuel J. Bensignor§ , David Robson¶, Kenneth V. Mason** , Rui Kano††  and Peter B. Hill‡‡ 

*Department of Clinical Sciences and Services, Royal Veterinary College, Hawkshead Lane, North Mymms, Hatfield, Hertfordshire, AL9 7TA, UK

†Department of Clinical Sciences and Advanced Medicine, School of Veterinary Medicine, University of Pennsylvania, 3900 Delancy Street, Philadelphia, PA 19104, USA

‡École nationale vétérinaire d'Alfort, BioPôle Alfort, EA 7380 Dynamyc, UPEC, EnvA, Maisons Alfort, Ile-de-France, France

§Clinique Vétérinaire, 17 Boulevard des Filles du Calvaire, Paris 75003, France

¶Animal Skin and Ear Specialists, Melbourne Veterinary Specialist Centre, 70 Blackburn Road, Glen Waverley, Victoria 3150, Australia

**Dermcare-vet PTY LTD, 7 Centenary Road, Slacks Creek, Queensland 4127, Australia

††Department of Veterinary Pathobiology, Nihon University College of Bioresource Sciences, 1866 Kameino, Fujisawa, Kanagawa 252-0880, Japan

‡‡Department of Veterinary Science, University of Adelaide, Adelaide, South Australia 5005, Australia

Correspondence: Ross Bond, Department of Clinical Sciences and Services, Royal Veterinary College, Hawkshead Lane, North Mymms, Hatfield, Hertfordshire, AL9 7TA, UK. E-mail: rbond@rvc.ac.uk

Background – The genus *Malassezia* is comprised of a group of lipophilic yeasts that have evolved as skin commensals and opportunistic cutaneous pathogens of a variety of mammals and birds.

Objectives – The objective of this document is to provide the veterinary community and other interested parties with current information on the ecology, pathophysiology, diagnosis, treatment and prevention of skin diseases associated with *Malassezia* yeasts in dogs and cats.

Methods and material – The authors served as a Guideline Panel (GP) and reviewed the literature available prior to October 2018. The GP prepared a detailed literature review and made recommendations on selected topics. The World Association of Veterinary Dermatology (WAVD) Clinical Consensus Guideline committee provided guidance and oversight for this process. The document was presented at two international meetings of veterinary dermatology societies and one international mycology workshop; it was made available for comment on the WAVD website for a period of six months. Comments were shared with the GP electronically and responses incorporated into the final document.

Conclusions and clinical importance – There has been a remarkable expansion of knowledge on *Malassezia* yeasts and their role in animal disease, particularly since the early 1990's. *Malassezia* dermatitis in dogs and cats has evolved from a disease of obscurity and controversy on its existence, to now being a routine diagnosis in general veterinary practice. Clinical signs are well recognised and diagnostic approaches are well developed. A range of topical and systemic therapies is known to be effective, especially when predisposing factors are identified and corrected.

Accepted 20 August 2019

Note: A shortened version of this review, comprising the summaries from each section, can be found at <https://doi.org/10.1111/vde.12834>.

Sources of Funding: This study was self-funded.

Conflicts of Interest: In the past five years, Ross Bond has received funding from or otherwise collaborated with Dechra Veterinary Products, Bayer Animal Health, Ceva Animal Health, MSD Animal Health and Elanco.

Daniel O. Morris has received honoraria, consulting fees and/or has collaborated with Pfizer Animal Health/Zoetis, Bayer, and Ceva Animal Health.

Jacques Guillot has received funding from or otherwise collaborated with MSD Animal Health, Ceva Animal Health, Bayer Animal Health and Boehringer-Ingelheim.

Emmanuel Bensignor has consulted and lectured for Elanco and Ceva Animal Health.

David Robson has received funding from or otherwise collaborated with MSD Animal Health, Virbac Animal Health and Elanco.

Kenneth V. Mason is Managing Director of Dermcare-vet PTY LTD.

Rui Kano has no conflicts of interest to declare.

Peter B. Hill has received honoraria and consulting fees from Pfizer/Zoetis and Elanco/Novartis.

Presented in draft form at the 2018 North American Veterinary Dermatology Forum, Maui, Hawaii, USA, the 2018 International Society for Human and Animal Mycology *Malassezia* Workshop, Utrecht, The Netherlands, and the 2018 European Society/College of Veterinary Dermatology Annual Congress in Dubrovnik, Croatia.

Table of Contents

1 Introduction	29
2 The genus <i>Malassezia</i> . General properties, phylogeny, genomic studies and species of relevance to veterinary medicine	29
3 Historical aspects of <i>Malassezia</i> yeasts as skin pathogens in dogs and cats	31
4 Ecology and epidemiology	33
5 Pathogenesis: virulence attributes amongst <i>Malassezia</i> yeasts	35
6 Pathogenesis: immunological responses to <i>Malassezia</i> yeasts and their clinical relevance in diagnosis/therapy	37
7 Predisposing factors for development of <i>Malassezia</i> dermatitis	40
8 Quantification of <i>Malassezia</i> populations on canine and feline skin by cytology and culture	41
9 Diagnostic methods: molecular and mass spectrometry identification of yeasts in culture and skin	45
10 Histopathological features of canine and feline <i>Malassezia</i> dermatitis	46
11 Antifungal susceptibility testing and resistance	47
12 Clinical presentations in dogs	50
13 Clinical presentations in cats	52
14 Summary of the diagnostic approach	53
15 Therapy	54
16 Prevention of <i>Malassezia</i> -associated skin diseases in dogs and cats	58
17 <i>Malassezia</i> yeasts as zoonotic agents	60
References	61

1 Introduction

Scientists have been grappling with the complexity of the genus *Malassezia* and their associated diseases for decades. Their relevance to companion animal veterinary practitioners first became apparent in the context of canine otitis externa in the 1950's, whereas their role in canine dermatitis was not established until more recently. *Malassezia dermatitis* is now recognised as a common skin disorder in canine practice, although it is encountered more occasionally in feline practice.

The commissioning of this review by the World Association for Veterinary Dermatology (WAVD) is timely, given the marked advances in our understanding of these lipophilic yeasts as a consequence of significant scientific endeavour, not least the sequencing of the genomes of the majority of the recognised species. Molecular biological techniques have transformed the taxonomy of the genus from two species in 1989 to 18 species at the time of publication, in the process explaining, at a stroke, many of the painstaking observations of phenotypic variation made by generations of mycologists.

This is the second WAVD consensus document on superficial veterinary mycoses, following on from one for dermatophytosis.¹ Whilst the headline title of our review is "diagnosis and treatment", the complexity of *Malassezia dermatitis* in dogs and cats requires a wider-ranging review. Unlike the dermatophytes, which visit and potentially infect the non-immune host, *Malassezia* yeasts are commensal organisms, forming a reservoir of potential pathogens in the stratum corneum or mucosae, that may induce disease whenever the homeostatic balance of yeast virulence, on the one hand, and host immunity, on the other, is disrupted in favour of the yeast.

Our review includes a full description of the genus, since six of the currently recognised species have been described on dogs and cats, and six more have been described in other species encountered by veterinary practitioners. The wide range of methods used to define and quantify *Malassezia* yeasts on skin is assessed; rarely does one investigator use the same method as the next, but the different methods often yield diverse and conflicting data; highlighting the strengths and weaknesses of each should promote careful method selection for future studies. A basic description of molecular methods is incorporated to aid the non-specialist reader in understanding how these techniques are currently applied to yeast identification and epidemiology, and how in future they may change our diagnostic approach to the case. A discussion of current concepts of yeast virulence and host immunity is a necessary prelude to a review of immunological methods in diagnosis and therapy, and in the context of the crucial consideration of the host predisposing factors, whose recognition and correction is key to the prevention of chronically-relapsing disease.

As the title indicates, one of our principal objectives is to describe the range of clinical presentations in dogs and cats, along with a suggested approach to elucidating the role, if any, of *Malassezia* yeasts in each case. Our therapeutic recommendations are drawn from both a systematic review of published therapeutic studies

(Section 15.2). Given the general paucity of high quality trials in this field, consensus views from the panel of authors have also been incorporated. Thus, our concluding summary of therapeutic options is a combination of evidence base and consensus of opinion.² Finally, in the spirit of a "one health" approach, the zoonotic potential of these yeasts is reviewed.

2 The genus *Malassezia*. General properties, phylogeny, genomic studies and species of relevance to veterinary medicine

Malassezia yeasts form a well-defined and unique cluster of lipophilic fungi living almost exclusively on the skin and mucosal sites of warm-blooded vertebrates. The genus *Malassezia* (Baillon) is usually considered as a monophyletic taxon in the phylum Basidiomycota and subphylum Ustilaginomycotina, a highly diversified group of more than 1,500 species of plant pathogens.³ Molecular analysis has confirmed that the genus *Malassezia* is deeply rooted in the Ustilaginomycotina with a sister relationship to Ustilaginomycetes and Exobasidiomycetes.⁴ As a consequence, it was proposed that the genus should be assigned as its own class, Malasseziomycetes.⁴ During the last decade, the analysis of the genome of *Malassezia* yeasts has allowed a better understanding of how these fungi, whose ancestors were most probably plant or soil residents, manage to survive and develop in the cutaneous ecosystem and how they interact with other members of the cutaneous microbiota. In 2007 the first genome sequence of a *Malassezia* species (*M. globosa*) was published.⁵ A few years later, a similar analysis was performed for *M. sympodialis*⁶ and for *M. pachydermatis*.⁷ In 2015, a study reported the sequences, assemblage and annotations for the genomes of 14 *Malassezia* species, including multiple strains of the most relevant species in medical dermatology (*M. globosa*, *M. sympodialis*, *M. restricta* and *M. furfur*).⁸

The first remarkable feature of *Malassezia* genomes is their small size (~10 Mb), about half of the size of other known basidiomycetous fungi, with some species having less than 4,000 predicted genes.^{5,8,9} This may reflect adaptation to the limited ecological niche of the yeasts. Gene family analyses indicate that *Malassezia* yeasts display unique characteristics comprising (i) a low carbohydrate-degrading capacity due to reduction of glycosyl hydrolase-encoding genes; (ii) a lipid dependence for growth due to lack of a fatty acid synthase gene and (iii) a concomitant expansion of lipid hydrolysing enzymes (such as secreted lipases, phospholipases and acid sphingomyelinases) that allow *Malassezia* yeasts to collect and use fatty acids from the skin or mucosal surfaces of their hosts. Analysis of the genomes also revealed the presence of unique genes with unknown function and which were probably acquired through horizontal gene transfer.⁸

The sexual form of *Malassezia* yeasts is still unknown. However, a region corresponding to the mating type locus (*MAT*) has been identified for these yeasts;⁶ it has been suggested that if there is an extant sexual cycle for

some of them that it is more likely to be bipolar or pseudo-bipolar, with two mating types, rather than tetrapolar as in many other basidiomycetous fungi.^{8,10}

On lipid-enriched media such as modified Dixon's agar, *Malassezia* colonies are cream to yellowish, smooth or lightly wrinkled, glistening or dull, with the margin being either entire or lobate. *Malassezia* yeasts appear as small ovoid, ellipsoidal or cylindrical cells (1.5 to 6.0 µm by 3.5 to 8.0 µm). Reproduction is by budding on a broad base and from the same site at one pole (monopolar blastic development). Some *Malassezia* species are able to form filaments in cutaneous lesions but also in culture under specific conditions.^{11–13} *Malassezia* yeasts have a thick cell wall (~0.12 µm) whose innermost layer shows a characteristic serrated structure.^{12,14–16}

The genus *Malassezia* (Baillon) was created in 1889 for a single species, *M. furfur*, observed in lesions of pityriasis versicolor, a common dermatological condition in humans.¹⁷ It took a long time to understand the lipid dependence of this kind of fungus and, as a consequence, to obtain and maintain *Malassezia* yeasts in culture.¹⁸ Conventional laboratory techniques could not be used and despite the description of numerous species, their accurate identification was not possible. In 1989, the genus *Malassezia* (Baillon 1889), also known under the generic name *Pityrosporum* proposed by Sabouraud in 1904, comprised only two taxa: *M. furfur* (syn. *P. ovale*, *P. orbiculare*), a lipid dependent species found on human skin and *M. pachydermatis* (syn. *P. pachydermatis*, *P. canis*), a species isolated from the skin of animals, especially dogs.

In 1990, Simmons and Guého described the new species *M. sympodialis* which was characterized by a sympodial budding process.¹⁹ In 1996, Guého *et al.*²⁰ had the opportunity to collect and examine many isolates from humans and animals. Conventional and modern spectrum techniques were employed to characterise these isolates, encompassing morphology, ultrastructure, physiology and molecular biology. The result was a complete revision

of the genus *Malassezia* and the description of four new species (*M. obtusa*, *M. globosa*, *M. slooffiae* and *M. restricta*).²⁰ Eleven more species were described subsequently by different groups and from varied hosts: *M. dermatitis*,²¹ *M. japonica*²² and *M. yamatoensis*²³ from humans in Japan; *M. nana*²⁴ from cases of otitis externa in cats and cattle; *M. caprae*²⁵ from goats; *M. equina*²⁵ from horses; *M. cuniculi*²⁶ from rabbits; *M. arunalokei*²⁷ from humans in India; *M. brasiliensis* and *M. psittaci*²⁸ from domesticated parrots in Brazil; and *M. verspertilionis* from bats in the USA²⁹. Of these, to date, *M. pachydermatis*, *M. furfur*, *M. sympodialis*, *M. globosa*, *M. slooffiae*, *M. nana*, *M. caprae*, *M. equina*, *M. cuniculi*, *M. brasiliensis*, *M. psittaci* and *M. verspertilionis* have been isolated from animals and are therefore relevant in veterinary dermatology (Table 1).

Malassezia species are lipid dependent due to an inability to synthesize long-chained (C14 or C16) fatty acids *de novo*.³⁰ There are some differences in lipid dependence among the species and this variability has been used for the development of specific tests for the identification.³¹ Historically *M. pachydermatis* was regarded as being "lipophilic but not lipid-dependent" because it was the only member of the genus to grow on Sabouraud's dextrose agar. Recently, genome sequencing has confirmed that *M. pachydermatis* lacks a fatty acid synthase gene like the other members of the genus, but is uniquely able to utilise lipid fractions within the peptone component of Sabouraud's dextrose agar for growth. These observations explain its failure to grow on lipid-free defined media and thus *M. pachydermatis* should now also be regarded as being "lipid-dependent".

The phenotypic identification scheme for the routine identification of *Malassezia* currently includes microscopic features, ability to use lipid supplements (different Tweens and cremophor EL [polyethoxylated castor oil]), catalase and beta-glucosidase reactions, and temperature tolerance at 32°C, 37°C and 40°C (Table S1). Despite the

Table 1. Summary of the taxonomy and ecology of the genus *Malassezia*

<i>Malassezia</i> species	Description and authors [reference]	Synonym	Presence in animals	Presence in humans
<i>M. furfur</i>	1889, (Robin) Baillon ¹⁷	<i>Pityrosporum ovale</i>	HS (dogs, cats, others)	HS, PV, fungaemia
<i>M. pachydermatis</i>	1925, (Weidman) Dodge ⁴⁷	<i>P. pachydermatis</i> , <i>P. canis</i>	HS + LS (dogs, cats, many others, mostly canids)	HS (dog contact), fungaemia
<i>M. sympodialis</i>	1990, Simmons & Guého ¹⁹	<i>M. furfur</i> serovar A	HS, OT (cats)	HS, AD, SD
<i>M. globosa</i>	1996, Midgley, Guého & Guillot ²⁰	<i>P. orbiculare</i> , <i>M. furfur</i> serovar B	HS, OT (cats)	HS, PV, SD, AD
<i>M. obtusa</i>	1996, Midgley, Guillot & Guého ²⁰	—	—	HS, LS
<i>M. slooffiae</i>	1996, Guillot, Midgley & Guého ²⁰	—	HS (pigs, cat claws)	HS, LS
<i>M. restricta</i>	1996, Guého, Guillot & Midgley ²⁰	<i>M. furfur</i> serovar C	—	HS, SD
<i>M. dermatitis</i>	2002, Sugita <i>et al.</i> ²¹	—	—	HS, AD
<i>M. japonica</i>	2003, Sugita <i>et al.</i> ²²	—	—	HS, AD, SD
<i>M. nana</i>	2004, Hirai <i>et al.</i> ²⁴	—	HS (cats, horses), OT (cats, cattle)	—
<i>M. yamatoensis</i>	2004, Sugita <i>et al.</i> ²³	—	—	HS, SD
<i>M. caprae</i>	2007, Cabañes & Boekhout ³¹¹	—	HS (goats)	—
<i>M. equina</i>	2007, Cabañes & Boekhout ³¹¹	<i>M. equi</i>	HS, LS (horses)	—
<i>M. cuniculi</i>	2011, Cabañes & Castilla ²⁶	—	HS (rabbits)	—
<i>M. arunalokei</i>	2016, Honnavar, Rudramurthy, & Prasad ²⁷	—	—	HS, SD
<i>M. brasiliensis</i>	2016, Cabañes <i>et al.</i> ²⁸	—	HS (parrots)	—
<i>M. psittaci</i>	2016, Cabañes <i>et al.</i> ²⁸	—	HS (parrots)	—
<i>M. verspertilionis</i>	2018, Lorch <i>et al.</i> ²⁹	—	HS (bats)	—

— not reported, AD atopic dermatitis, HS healthy skin, LS lesional skin, PV pityriasis versicolor, SD seborrhoeic dermatitis, OT otitis.

undisputable value of this phenotypic identification scheme, ambiguous results are sometimes reported. Furthermore, the addition of recently identified species resulted in similar physiological patterns and thus in a doubtful identification (*M. arunalokei* and *M. brasiliensis* are closely related to *M. restricta* and *M. furfur*, respectively) (Table S1). For all these reasons, specific identification should be confirmed by DNA sequencing analysis. Various molecular loci had been proposed to identify *Malassezia* species (Section 9). The most frequently used loci are the D1/D2 domain of the 26S rRNA gene and the internal transcribed spacer (ITS) regions.^{32,33} Other genes such as *chitin synthase-2*³⁴ and β -*tubulin*³⁵ have been proposed for taxonomic purposes. Recently, mass spectrometry has also been utilised for the identification of *Malassezia* yeasts isolated from human patients in three French university hospitals.³⁶ A MALDI-TOF database of main mass spectra has recently been developed to allow the rapid identification of 14 *Malassezia* species.³⁷

2.1 Conclusions

Malassezia yeasts are unique in several ways, including their strict dependence on lipids, their cellular ultrastructure and their dominance as eukaryotic residents on the skin of warm-blooded vertebrates. The taxonomy of the genus *Malassezia* is evolving. Eighteen species have been described so far but many other species are most probably present on the skin or mucosal sites of warm-blooded animals. Few phenotypic tests are available to differentiate *Malassezia* species and some of them may overlap. As a consequence, DNA sequencing (or other techniques like mass spectrometry) may be required for specific identification.

3 Historical aspects of *Malassezia* yeasts as skin pathogens in dogs and cats

3.1 Introduction: prehistory facilitating discovery

Analysis of the history of scientific discovery highlights the influence of language and geography, the role of experts and opinion leaders in study centres or in the modern day "centres of excellence", and wider cultural effects that may impede or enhance investigation and implementation of technological advances in the pursuit of scientific progress. The fascinating history of the genus *Malassezia* and its role in disease spans four centuries and three continents and extends from early microscopical observations through to present day genome sequencing. After a [final] flurry of controversy in the late 20th century, this body of evidence culminated in development of the disease model that veterinarians use today.

3.2 The first reports of the yeast and disease

3.2.1 Early reports

1846: Karl Ferdinand Eichstedt was the first to observe hyphal elements and blastoconidia in scale from his patients and attributed these to cause a human skin disease he called "Pityriasis versicolor".³⁸

1853: Charles Robin named Eichstedt's fungus as *Microsporon furfur*, believing it to be a dermatophyte, and termed the associated skin disease "Tinea versicolor".³⁹

1873: Sebastiano Rivolta, an Italian veterinarian, noticed a double-contour budding yeast in human "psoriatic" scales and gave them the name *Cryptococcus psoriaticus*.⁴⁰

1874: Frenchman Louis Charles Malassez⁴¹ suggested that *Microsporon furfur* caused dandruff and correctly differentiated the yeast into genus of single cell fungi ("*Saccharomyces*") rather than the dermatophyte complex. For this correction, his name was ultimately attached to the genus.⁴²

3.2.2 Attempts at classification without laboratory isolation

1884: Bizzozero studied these microbes and described them to be part of normal human skin flora. He claimed there were two different species and named them *Saccharomyces ovalis* and *S. sphaericus*.⁴³ However, these were later shown to be a single species.⁴⁴

1889: Baillon created the genus *Malassezia* to accommodate *M. furfur*, in honour of Malassez, who was already acknowledged as having described the new species – at least in the French-speaking scientific community.¹⁷ However this particular yeast could not be grown and isolated in laboratory conditions because its lipid requirement in culture media were as yet unknown.

1910: Raymond Sabouraud, a prominent medical mycologist, proposed the name *Pityrosporum malassezi* for this bottle shaped yeast thought to cause human dandruff.⁴⁵

1913: Alfred Kraus was able to culture *P. malassezi* in a medium containing lanolin.⁴⁶ In a prime example of the effect of geography and historical events on scientific discovery, this German scientist's work was largely overlooked with the onset of the First World War.

3.2.3 Diseases associated with *Malassezia*

1925: Weidman reported bottle shaped yeast from the scale of the single horned Indian rhinoceros (*Rhinoceros unicornis*) with a generalised exfoliative dermatitis.⁴⁷ In contrast to *M. furfur* this yeast cultivated readily on routine media without lipid supplementation. Weidman classified the yeast in the genus *Pityrosporum*, with the species name *P. pachydermatis*. The rhinoceros responded rapidly to topical therapy with 1% salicylic acid in lard.

1928–1929: McLeod and Dowling part-fulfilled Koch's postulates by isolation of *M. furfur* from humans with seborrhoeic dermatitis in an oleic acid broth.^{48,49} They then inoculated lesion-free skin of a person with seborrhoeic dermatitis and a normal human with the broth isolate and reproduced seborrhoeic lesions in both, from which they re-isolated *M. furfur*. An incidental finding was an association between the dandruff, yeast and a concurrent coccoid bacterium that was carefully separated and subcultured. MacLeod and Dowling regarded these pyogenic micrococci as secondary invaders, even accepting it was constantly associated with seborrhoeic dermatitis.⁵⁰ Interestingly, MacLeod and Dowling referred to three names of the yeast in their work: the "spore of Malassez", "Pityrosporum of Sabouraud" or the "flask bacillus of Unna". Until now, no consensus had been reached as to whether these names covered a single

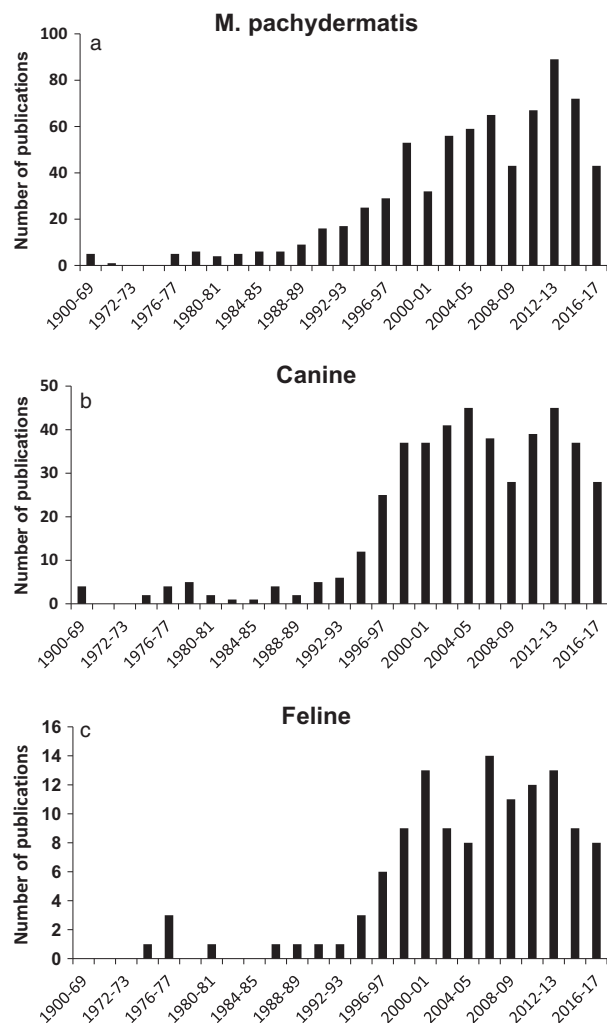


Figure 1. The numbers of publications on *Malassezia pachydermatis* by year (a) and for dogs (b) and cats (c) from 1900 to present day.

organism, whether it was pathogenic and what disease was caused. This work was later confirmed by Moore *et al.*⁵¹

These publications, discussions and controversies were a prerequisite to unravelling the role of *Malassezia* spp. in skin diseases of the dog and cat.

3.2.4 The controversy and 'Dark Years': 1940 to 1960

1940–1960: are known as the 'Dark Years' and spanned a period of more controversy. The hard won progress in the field was forgotten as a consequence of the Second World War and the overwhelming effect of cortisone treatment becoming available in the late 1940s, to which human seborrhoeic dermatitis responded. The role of *Malassezia* yeasts in the disease was thus forgotten.

1970: The systematics were rectified when Sloff in Lodder's 'The Yeasts, a taxonomic study' assigned all *Pityrosporum* that grew on media without lipid enrichment as single species of *P. pachydermatis*.⁵²

1984: The third edition of "The Yeasts, a Taxonomic Study" (Yarrow and Ahearn) referred to the new genus *Malassezia* and confirmed that one species grew without lipid enrichment.^{53,54} This was later officially added into the taxonomical order.⁵⁵

1990: A new species, *Malassezia sympodialis* was described¹⁹ and by 1996 four new species were added to the genus.²⁰ This species was later isolated from a cat by Bond *et al.* in 1996.⁵⁶

3.2.5 Modern approaches

Currently there are 18 different species of *Malassezia*.^{35,57} The genus continues to expand and this is likely to continue as the classical 'bottom-up' microbiological approaches merge with organism-level genomics and community or "systems-level meta-genomics".

3.3 *Malassezia* yeasts in animals

3.3.1 Canine ear and skin disease: the first reports (1951 to 1999)

The discovery of *Malassezia* in animals occurred at a much later date than in humans. As mentioned, Weidman⁴⁷ isolated yeasts from the skin of a rhinoceros in 1925, but research in domestic animals largely re-started 30 years later.

3.3.2 *Malassezia* yeasts in the canine and feline ear

1955: Gustafson was the first to notice a bottle shaped yeast in otitis externa of a dog; he correctly recognized them as *Pityrosporum* and created a new species *P. canis*.⁵⁸ This was in error as he had misread Lodder's description and failed to consider Weidman's discovery of the yeast in rhinoceros skin, which grew without lipid enrichment. Gustafson was able to induce a spontaneously-resolving erythematous-ceruminous otitis externa in healthy dogs by the application of a suspension of '*P. canis*' to the external ear canal.⁵⁸

1961: Fraser also isolated and studied strains of yeast from healthy and diseased dog ears and correctly ascribed all as *P. pachydermatis*. During the next two decades, a number of studies showed the connection between canine otitis externa and *P. pachydermatis*.^{59,60}

1976: Baxter also showed that, unlike previously thought, the frequency of isolation of *P. pachydermatis* was comparable in healthy ears and in cases of otitis externa in dogs' and cats' ears.⁶¹

3.3.3 Canine skin disease

1975: Dufait was the first to describe the skin disease, albeit in a local veterinary journal written in Dutch.⁶² Also later, several non-English language studies were published,^{63–65} all describing canine *Malassezia* dermatitis; however, without a widespread English audience, many pruritic dogs suffered as a result of this disadvantage.

1987: Mason⁶⁶ spoke about three canine *Malassezia* dermatitis cases at the American Academy/College of Veterinary Dermatology meeting, creating objection and controversy, although another speaker from private speciality practice advised that he has seen a similar case. Similar discussions ensued at a lecture in 1992 at the British Veterinary Dermatology Study Group spring meeting.⁶⁷ One highlight of the debate was mention of Shuster's publication that showed that dandruff was clearly associated with "*Pityrosporum ovale*", elegantly dismissing the distorted view that effective dandruff treatments were cytostatic rather than antimycotic in action.⁶⁸

1988: Larsson *et al.*⁶⁹ drew attention to *Malassezia* skin disease in the English language by describing the skin disease associated with *P. pachydermatis*. Mason and Evans confirmed and expanded on those earlier observations,⁷⁰ although acceptance by the veterinary profession was not universal.

1992: Pedersen published in Danish a case series of 10 dogs with *Malassezia* dermatitis.⁷¹ He described the cytology, mycology, histopathology and the results of antifungal treatment. The before and after clinical photographs left no doubt about the dramatic health and welfare benefits of the antifungal therapy in these cases.

1996: Mason *et al.*⁷² followed up on knowledge of *Malassezia* associated dermatitis, staphylococcal pyoderma and demodicosis and integrated these into a unifying concept of skin commensals as opportunistic and complementary pathogens. By this time, the initial controversy that had dogged the profession regarding the significance of *Malassezia* yeasts as a cause for dermatitis in the canine had largely settled.

Present day: Currently, *Malassezia pachydermatis* is now well-recognized as a commensal yeast of dog's skin and mucosa; overgrowth is commonly associated with otitis externa and dermatitis. Research continues in further characterising the relative pathogenicity of the different species and genotypes, and elucidating the factors that drive the conversion to pathogen (Figure 1a–c).

3.3.4 *Malassezia* yeasts in cats: rare or common?

The role of *Malassezia* spp. in feline skin disease beyond the ear canal had not aroused much interest until the research into canine and human *Malassezia* spp. carriage and associated dermatitis prompted some further work in the mid to late 1990's.

1976: Baxter was the first to report on *M. pachydermatis* in cat ears and as previously mentioned, found that *Malassezia* were also present in the ears of healthy animals.⁶¹ In 1990 Hajsig and Hajsig confirmed that *M. pachydermatis* is a normal part of cat skin microflora.⁷³

At the time *Malassezia* dermatitis was considered extremely rare or unknown in the cat. A causal relationship between the overgrowth of *Malassezia* in the cat and the development of seborrhoeic dermatitis was proposed in 1994.⁷⁴ The two cats discussed had generalized exfoliative and greasy erythroderma which responded to antifungal therapy.

1996: The isolation of *M. globosa* from skin of a healthy cheetah (*Acinonix jubatus*) represented the first report of lipid-dependent *Malassezia* spp from Felidae.^{20,75} Bond *et al.*⁵⁶ isolated the first lipid dependent species (*Malassezia sympodialis*) from domestic cat skin. Subsequent studies by the same group and other groups in Spain and Japan led to reports on the isolation of *M. globosa*,⁷⁶ *M. furfur*,^{77,78} *M. nana*^{24,79} and, more recently, *M. slooffiae*^{80–82} from domestic cats.

2002: Mauldin *et al.*⁸³ evaluated the presence of *Malassezia* yeasts in feline skin specimens submitted for histopathological examination from 1999 to 2000. Of the 15 cats with *Malassezia*, 11 presented with an acute onset of multifocal to generalized skin lesions and were euthanised or died within two months. In contrast to humans and dog, *Malassezia* overgrowth in the cat, in the absence

of hypersensitivity disorder or a breed predilection (Devon rex, sphynx) may indicate a poorer prognosis due to an association with life-threatening systemic diseases.

2005: Cafarchia *et al.*⁸⁴ reported that both the frequency of isolation and population sizes of *M. pachydermatis* was increased in cats with otitis externa, when compared with healthy cats.⁸⁴

2007: Cats with seborrhoeic and allergic presentations were shown to have concurrent *M. pachydermatis* overgrowth that responded clinically to azole antifungal therapy, in parallel to the situation in dogs.^{80,85,86}

3.4 Conclusions

The history of the association between *Malassezia* yeasts and its animal hosts has been long mired in controversy. Recent genomic studies have elucidated previously problematical aspects of taxonomy and indicated that genotypes and species of *Malassezia* are evolving as an adaptation to particular host ecological niches. Having been previously overlooked, canine *Malassezia* dermatitis has evolved from a controversial to a routine now diagnosis in small animal practice, with very significant welfare benefits for many animals.

4 Ecology and epidemiology

4.1 Introduction

Malassezia yeasts are common skin commensals in warm-blooded vertebrates. The loss of fatty acid synthetase genes (Section 2), resulting in a requirement for a lipid source for growth, is likely one factor linking them to animal hosts. In one review,⁸⁷ it was proposed that *Malassezia* yeasts are potential pathogens that operate in a pliable, physiological "transitional mantel zone" that is influenced by both host skin and the animal's external environment. Thus, yeast proliferation may be enhanced by either favourable environmental conditions (heat, humidity) and or changes in host susceptibility (Section 7).

Many culture-based studies have been carried out worldwide both in humans and in animals (especially in dogs) to better understand the ecology of *Malassezia* species on healthy skin and in cases with cutaneous lesions.³³ Results are rarely comparable between studies because of the use of different sampling procedures, culture media and identification techniques. The influence of sampling methods and culture media on yeast counts are reviewed in Section 8. The general conclusion is that *M. pachydermatis* remains by far the most important and prevalent species in dogs while the other lipid-dependent species are detected quite frequently in certain animal species (like cats) or body sites. Some of these lipid-dependent species seem to be host-specific (Table 1). In humans, three species (*M. globosa*, *M. restricta* and *M. sympodialis*) predominate.⁸⁷ Interestingly human-related species may have a different geographical distribution; *M. dermatis* has been isolated in East Asia, *M. arunalokei* in India, whereas *M. obtusa* was mostly reported from Sweden, Canada, Bosnia and Herzegovina.^{27,33}

Malassezia yeasts have been isolated from almost all domestic animals, different wild animals in captivity and also from wildlife. An exhaustive list of potential animal

hosts was reported in 2010.⁸⁸ In addition, the presence of *Malassezia*-like organisms has been reported in a wide range of environmental habitats, from deep sea sediments, hydrothermal vents and arctic soils, to marine sponges, stony corals, eels, lobster larvae and nematodes.^{89–91}

In recent years methods based on next generation sequencing (NGS) have allowed a better characterization of the complex microbial communities occurring on the skin and made it possible to detect *Malassezia* species that would otherwise be missed using culture-based methods (Section 4.4).

4.2 Ecology of *Malassezia* yeasts in dogs

Colonisation of canine skin probably occurs in the very first days of life; how this occurs is not understood but likely involves transfer from the bitch's flora following removal of the amniotic membrane, licking and nursing in the same manner as staphylococci.⁹² In a study performed in 22 newborn Rottweiler puppies, *Malassezia* yeasts were recovered from around 40% of samples collected from the lips, nail beds and ears, at three, seven and 35 days of age.⁹³

Several investigators have explored *Malassezia* colonization in various anatomical regions of different breeds of adult healthy dogs; example studies that utilised culture methods are summarised in Table S2. There is some variability in the data, reflecting in part varied sampling methods; however, it can be seen that the sites most frequently colonised by *M. pachydermatis* in healthy pet dogs of various breeds are the peri-oral/ lip region (81% of 58 dogs sampled using contact plates) and interdigital skin ((60–70% of 40 dogs sampled using contact plates) whereas the yeast is less-often detected in the skin of the axilla (12.5% of 40), groin (23% of 91) and dorsum (4% of 73). The perianal skin and anal mucosa is a frequent (~55% of 73 dogs) carriage site whereas nasal and oral carriage is less frequent. Using cytological techniques, it was reported that the highest number of *Malassezia* were on the chin region, while inguinal and axillary zones presented the lowest number.⁹⁴ *Malassezia* yeasts were identified by cytological methods in 10–31% of examined anal sacs in two studies of groups of healthy dogs (n = 57),⁹⁵ usually in low numbers.^{95,96} *Malassezia* yeasts were detected on the periocular skin of only three out of 56 (5%) clinically normal dogs.⁹⁷ Basset hounds show a marked breed variation, with significantly increased frequencies and population sizes of *M. pachydermatis* in the nose, mouth, vulva and axilla.⁹⁸

Studies of oral carriage of *Malassezia* may have relevance as a source of transfer to the skin.^{99–101} Twice-weekly application of a miconazole-chlorhexidine shampoo to seborrhoeic Basset hounds resulted in a significant reduction of *M. pachydermatis* populations in both the skin and mouth.⁹⁹ Another study pointed out the possible transfer of *Malassezia* yeasts between the perioral area and pruritic skin lesions of the inguinal area as a consequence of frequent licking, and between undamaged interdigital regions as a result of persistent scratching.¹⁰²

Other than *M. pachydermatis*, lipid-dependent *Malassezia* yeasts are infrequently reported from dog skin. In initial reports, the identification of lipid-dependent yeasts

was based only on morphological and physiological characteristics.^{84,103,104} In the absence of molecular techniques, there is scope to confuse lipid-dependent *Malassezia* spp. with atypical strains of *M. pachydermatis* that show inconsistent or stable lipid-dependence.^{105,106} However, the presence of *M. furfur* was confirmed by molecular biology in dogs with cutaneous lesions¹⁰⁷ or otitis¹⁰⁸ in Brazil. In a survey in Slovakia, mycological cultures performed from dogs with cutaneous lesions (n = 118) and dogs with otitis externa (n = 328) yielded *M. pachydermatis* as the most frequently isolated species (121 isolates); however, four lipid-dependent isolates were identified as *M. furfur* and one as *M. nana*.¹⁰⁹

4.3 Ecology of *Malassezia* yeasts in cats

The skin of Felidae is colonized by a diverse array of *Malassezia* spp yeasts. Whilst *M. pachydermatis* is most frequent, as in dogs, the lipid-dependent species isolated from domestic cats include *M. sympodialis*,^{56,76} *M. globosa*,⁷⁶ *M. furfur*,^{77,78} *M. nana*,^{24,79} and *M. slooffiae*.^{80–82} The original reports of isolation of *M. furfur* are based on phenotypic rather than molecular methods. The isolation of *M. globosa* from the skin of a healthy cheetah (*Acinonix jubatus*) represented the first report of lipid-dependent *Malassezia* spp from cats.^{20,75} In 2004, a study described *M. nana*, a novel species from aural discharges of a cat and cattle.²⁴ Some lipid-dependent strains similar to the *M. sympodialis* type strain and isolated from cats were studied using DNA sequence analysis and grouped together with *M. nana*.¹¹⁰ *Malassezia nana* seems to be the most common lipid-dependent species isolated from cats, particularly in the ear canal; similarities in the sequences of three loci of the rRNA gene,¹¹¹ β -tubulin gene and microsatellite profiles¹¹² indicate that a particular *M. nana* genotype predominates in this host. *Malassezia slooffiae* is primarily but not exclusively associated with the feline claw fold.⁸⁰

Malassezia pachydermatis is less frequently isolated from cats than from dogs.^{73,75} Marked variations in *Malassezia* populations have been reported in the external ear canal of healthy cats. One study identified *Malassezia* yeasts in 43 out of 52 healthy cats sampled in the winter months in north eastern USA.¹¹³ By contrast, another study failed to identify yeasts in 20 health cats sampled in France; notably in the latter study, the presence of cerumen was an exclusion criterion whereas cerumen was noted in many of the US cats, especially amongst those with a purely indoor lifestyle.¹¹⁴ *Malassezia* yeasts were detected in 20% (six of 30) ear canals of 15 cats with disease and in 43% (13 of 30) ear canals of 15 allergic cats.¹¹⁴ Devon rex cats and sphynx cats, but not Cornish rex cats, are prone to high carriage rates of *Malassezia* yeasts and a generalised seborrhoeic dermatitis that responds to oral itraconazole.^{80,86,115,116} Predisposing factors such as hypersensitivities and internal diseases that disrupt cornification are reviewed in Section 7.

4.4 *Malassezia* yeasts as components of the cutaneous microbiome

The original cutaneous microbiome studies mainly focused on prokaryotic inhabitants; thereafter fungi received more attention in humans and also in dogs and

cats.^{117,118} The first large-scale sequencing analysis which evaluated fungal diversity ("mycobiome") on human skin clearly demonstrated that *Malassezia* yeasts are the most abundant fungal organisms on many human skin sites, as previously shown for the scalp.^{119–121} In contrast to extensive bacterial diversity found at all human skin sites tested,¹²² the fungal diversity seems more site-dependent.¹²¹ Eleven *Malassezia* species were identified with *M. restricta* being predominant in the external auditory canal, retroauricular crease and glabella; while *M. globosa* was on the back, occiput and inguinal crease. The remaining species were detected across other body sites and with lower frequency.¹²¹ Reanalysis of these metagenomic datasets using a more complete set of *Malassezia* genomes demonstrated the presence of 12 species, with *M. restricta* and *M. globosa* by far the most abundant, distantly followed by *M. sympodialis*.⁸ The metagenomic analysis of skin samples from 40 asymptomatic individuals in Hong Kong revealed that 90% of the sequencing reads matched to *M. restricta*.¹²³ Another study investigating 40 asymptomatic individuals in Japan indicated that *Malassezia* population differed by sex, body part and season.¹²⁴ Another study reported a significant decrease in community diversity as an indication of skin disease in humans.¹²⁵

Only a very few studies examined the skin microbiota in dogs and cats.^{117,118,126–128} One study suggested that the main force driving the variability in microbiota composition was the individual, rather than the breed, hair coat or the skin site.¹²⁶ Another study used NGS to define a much more diverse cutaneous mycobiota than that previously described with culture-based techniques in studies of healthy and allergic dogs.¹¹⁸ The cutaneous mycobiota appeared to be influenced by various factors including environmental exposure, cohabitation with other pets and skin health status. Surprisingly, *Malassezia* yeasts were not the most abundant fungal organisms on healthy canine skin. Sequences corresponding to filamentous contaminants from the environment (*Alternaria*, *Cladosporium* and *Epicoccum* spp.) were predominant. Furthermore, the same study was unable to detect any significant differences in the relative abundance of *Malassezia* yeasts between healthy and allergic dogs.¹¹⁸ In a similar metagenomic analysis performed in healthy and allergic cats, the most abundant fungal sequences were identified as filamentous contaminants from the environment (*Cladosporium* and *Alternaria* spp.) and not *Malassezia* yeasts, which were identified in 30% (35 of 108) and 21% (eight of 39) of healthy and allergic cat samples, but rarely accounted for more than 1% of the relative fungal abundance.¹¹⁷

4.5 Conclusions

Malassezia pachydermatis is a normal inhabitant of healthy canine skin and mucosae. *Malassezia pachydermatis* also predominates in the skin of the domestic cat, although other species are occasionally identified, particularly *M. nana* in the ear canal and *M. slooffiae* in the claw fold. Population sizes vary markedly between anatomical sites, and between different breeds. These commensal *Malassezia* populations provide a reservoir of yeasts that might proliferate and/or induce an inflammatory response under the influence of various host predisposing factors.

5 Pathogenesis: virulence attributes amongst *Malassezia* yeasts

The interactions between *Malassezia* yeasts and the skin of their hosts, and the factors which influence transition from commensal to pathogen, are the subject of intensive scientific endeavour, especially pertaining to the common pathogens of humans (*M. globosa*, *M. sympodialis*, *M. restricta* and *M. furfur*).^{33,129} Comparative genomic studies following the sequencing of 14 *Malassezia* species have significantly advanced opportunities for understanding of the adaptation of the genus to its limited ecological niches (mainly skin), elucidation of virulence attributes necessary for colonisation and infection, and identification of novel interventional targets for therapy.⁸ In particular, the novel description of *Agrobacterium tumefaciens*-mediated transformation systems that allows for the insertion of transfer DNA and targeted gene deletion in *M. furfur*, *M. sympodialis* and *M. pachydermatis*, and thus analysis of individual gene function, is certain to revolutionise our understanding of the biology of this genus.^{130–132}

The presence of a nutritionally absorptive fungus within the stratum corneum exposes the host to an array of chemicals, immunogens and allergens, comprising fungal cell wall-associated carbohydrates, proteins and lipids; secreted enzymes that generate both substrates for nutrition and an array of irritant metabolic by-products. The cell wall of *Malassezia* spp. is unusual in thickness (90–150 nm^{14,133}), morphology (inner spiralling/corrugation^{14,133,134}) and composition (predominance of (1 → 6)-β-D-glucan, trace of mannan¹³⁵ with unusual polysaccharide assembly¹³⁶, chitin prominent in bud-scar¹³⁷, lipid-rich wall and capsule⁶) (Figure 2). Interaction with other commensal microbes might also influence pathogenicity and expression of virulence factors.^{138–140} Thus, these commensal yeasts are likely highly regulated by

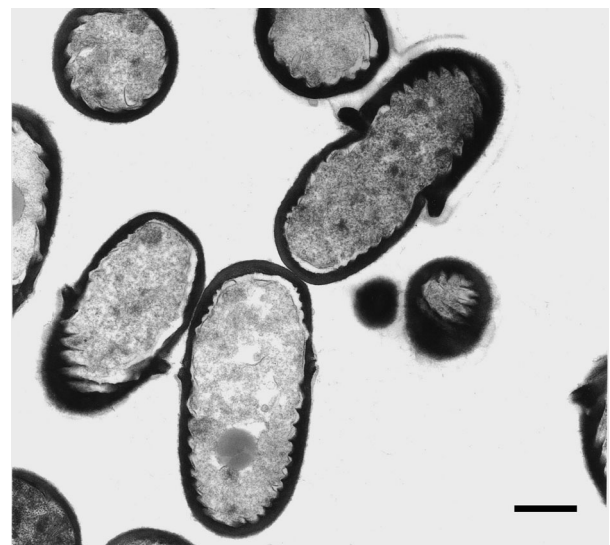


Figure 2. Transmission electron micrograph of *Malassezia pachydermatis*. Cells have a thick cell wall with characteristic inner spiralling. Monopolar blastic development is associated with a prominent bud scar. Scale bar = 500 nm.

continuous interactions with the host immune system (Section 6)¹⁴¹ and these interactions ultimately determine whether the outcome is inflammation (i.e. fungal disease) or not.

Adherence, the specific attachment of the microbe to host cells, is a key step in colonisation and infection of animals by commensal and pathogenic fungi.¹⁴² Adherence of *M. pachydermatis* to canine corneocytes has been reviewed in detail,¹⁴³ and likely involves a small family of proteins that are covalently bound to cell wall carbohydrate and anchored to the plasma membrane.⁶ *Malassezia* cells adhering to keratinocytes have the potential to modulate the expression of an array of cytokines, chemokines and antimicrobial peptides, the outcome of which may be immune-stimulatory (as may occur in disease states, characterised by the development of cutaneous inflammation) or immune-suppressive (promoting commensal carriage)¹⁴⁴ as reviewed.¹⁴³ A change in host immunity, altered skin microclimate or disruption in epidermal physiology associated with concurrent diseases (Section 7) may predispose animals to clinical disease. Co-proliferation of staphylococci in the same lesions¹⁴⁵ may exacerbate clinical signs and necessitate concurrent antibacterial therapy in some cases.¹⁴⁶ The term 'dysbiosis' has been applied to similar microbial imbalances within the cutaneous microbiome, albeit primarily in the context human and canine atopic dermatitis (cAD).^{118,147–149}

The *Malassezia* genus' evolution to lipid-dependency is associated with a wide expansion of lipase and phospholipase genes, and loss of carbohydrate metabolism genes, although numbers of secreted proteins overall appear lower than those of related plant pathogens (Section 2).¹⁵⁰ Lipases, highly expressed in the skin of human patients with dandruff and seborrhoeic dermatitis, likely damage the epidermal barrier directly and by hydrolysis of triglycerides.^{151–153} Phospholipase activity in *M. pachydermatis* is stimulated by the endogenous opioid peptide β endorphin present in the skin of dogs with dermatoses;¹⁵⁴ activity was significantly higher amongst *M. pachydermatis* isolates derived from the dogs with otitis externa¹⁵⁵ or skin lesions^{156,157} when compared with those obtained from the dogs with healthy external ears, or non-lesional skin, respectively. Similar observations have been made in pathogenic strains of *M. restricta* and *M. globosa* collected from lesions of seborrhoeic dermatitis in humans.¹⁵⁸ Genotypic variants of *M. pachydermatis* with high phospholipase activity induced higher expression of pro-inflammatory genes from cultured human keratinocytes.¹⁵⁹ Laboratory data indicated that phospholipase production might act in synergism with biofilm formation (layers of adhering yeasts embedded in variable quantities of extracellular matrix) to induce or exacerbate skin lesions in dogs.¹⁶⁰ By contrast, a secreted aspartyl protease from *M. globosa* inhibited *S. aureus* biofilm proliferation and rapidly hydrolysed protein A, a major staphylococcal virulence factor.¹³⁹ A correlation between biofilm formation and other virulence factors (hydrophobicity, adherence) was observed amongst 60% of 16 clinical isolates of *M. furfur*.¹⁶¹ The role of biofilm formation in potentially reducing susceptibility to

antifungal drugs is discussed in Section 10. Other enzymes from *Malassezia* yeasts such as acid sphingomyelinases and chitin deacetylases may also influence host-yeast interactions.¹⁶²

Malassezia yeasts from human skin have the ability to synthesise *in vitro* a large panel of indolic compounds (mainly malassezin, indolo[3,2-b] carbazole, pityriacitrin, pityrialactone and indirubin) when tryptophan is used as the single nitrogen source.³³ These indoles act as potent ligands for the aryl hydrocarbon receptor (AhR), a nuclear receptor and transcriptional regulator with pleiotropic effects that include down-regulation of immune stimulation, modification of melanogenesis and epidermal cell function, and inhibition of antagonistic microbes.^{152,163} One study suggested that *M. pachydermatis* is able to induce activation of the AhR in human keratinocytes and to increase the expression of responsive genes and markers of epidermal differentiation.¹⁶⁴ Since indole production was not detected in a study of 80 *M. pachydermatis* strains from canine otitis externa,¹⁶⁵ AhR activation by *M. pachydermatis* might be associated with the release of compounds other than indolic metabolites.

Malassezia cell wall carbohydrates have been long-recognised as IgE binding epitopes in humans with AD^{166,167} while other studies have highlighted their importance in fungal cell recognition by host phagocytic cells.¹⁶⁸ C-type lectins are proteins that bind carbohydrates in a calcium-dependent (hence C) manner via highly-conserved carbohydrate-recognition domains.¹⁶⁸ Langerin, a C-type lectin expressed by Langerhans cells that recognises mannose and beta-glucans, has a strong affinity for *Malassezia* and *Candida* spp. and is regarded as a major pattern recognition receptor for both commensal and pathogenic fungi.^{169,170} By contrast, Mincle, a C-type lectin expressed by activated phagocytes that binds glucosyl and mannosyl-glycolipids from *M. pachydermatis* and *M. sympodialis*,¹⁷¹ selectively recognises *Malassezia* spp. but not other fungi.¹⁷² In co-operation with Dectin-2, another C-type lectin that recognises a distinct hydrophilic O mannobiose-rich protein, Mincle and Dectin-2 collaborate to enhance production of inflammatory cytokines such as TNF- α , MIP-2 and IL-10 from mouse activated phagocytes exposed to *Malassezia furfur*.¹⁷¹ C-type lectin-mediated innate immune mechanisms are discussed further in Section 6.

5.1 Conclusions

There have been significant advances in the understanding of the mechanisms of interaction between *Malassezia* yeasts and their hosts. The outcome of *Malassezia* growth in the stratum corneum is dependent upon the metabolic activities of the yeasts (expression of cell wall and secreted virulence attributes) and the host's innate and adaptive immune defensive responses; interactions with other skin commensals (especially staphylococci) may also play a role. All these processes should ideally result in a delicately balanced homeostatic relationship. Further studies are required to define fully the parameters that dictate transitions between commensalism and parasitism that may yield opportunities for novel preventative and therapeutic strategies.

6 Pathogenesis: immunological responses to *Malassezia* yeasts and their clinical relevance in diagnosis/therapy

The presence of *Malassezia* organisms on the skin, both in normal and excessive numbers, is known to activate the skin immune system.¹⁷³ There is now compelling evidence that *Malassezia* antigens can stimulate innate, antibody and cell mediated immune responses, as well as triggering hypersensitivity reactions.¹⁷⁴ Although this immune response may offer a degree of protection in certain circumstances, it may also be harmful. In animals in which an overgrowth of organisms has occurred, or in individuals that are predisposed to allergic sensitization, the ensuing inflammatory response can lead to clinical signs such as dermatitis and pruritus. This section comprises a comparative review of human and dog studies; publications on immune reactivity to *Malassezia* species in cats appear to be lacking.

6.1 Activation of keratinocytes

The initial interplay between *Malassezia* organisms and the skin immune system is likely to take place in the epidermis.¹⁷⁵ It has been demonstrated that application of *M. pachydermatis* suspensions on healthy dog skin can induce skin lesions similar to those observed in naturally occurring *Malassezia* dermatitis.¹⁷⁶ This indicates that *Malassezia* cell surface markers or metabolic products derived from the yeast may be able to directly damage the skin or induce pathogenic effects by activating the skin immune system.¹⁷³ In order for this to happen, antigens or allergens produced or expressed by *Malassezia* spp. would need to penetrate the stratum corneum in order to be recognised by Langerhans cells or keratinocytes. These would then act as antigen presenting cells able to sensitise and then activate the T lymphocyte population. An impaired barrier function, such as is seen in canine and human atopic dermatitis,¹⁷⁷ is likely to facilitate transepidermal allergen penetration. Activation of keratinocytes by *Malassezia* is suggested by studies in humans which demonstrated that *M. furfur* could invade keratinocytes and resist phagolysosome fusion.^{178,179} Furthermore, *M. sympodialis* produces extracellular vesicles, enriched with the allergens Mala s 1 and s 7, that bind actively to and are internalised by human keratinocytes, potentially promoting sensitisation and maintenance of inflammation.¹⁸⁰

Keratinocytes recognise *Malassezia* antigens via Toll-like receptors,¹⁷⁴ although they, along with other cells, can also be activated via the aryl hydrocarbon receptor following stimulation with *Malassezia furfur*-derived indole alkaloids such as malassezin, indirubin and indolo carbazole.¹⁷⁵ These tryptophan-derived metabolites can trigger a variety of effects such as apoptosis of human melanocytes, but their precise role in cutaneous pathology remains to be determined. Once activated, keratinocytes can alter their cytokine expression, with up-regulation of the immunosuppressive cytokines IL-10 and TGF- β and down-regulation of the inflammatory cytokine IL-1 α .¹⁸¹ Contradictory results have been reported for IL-6 and TNF- α with some studies demonstrating up-regulation and others showing down-regulation.¹⁸¹

Keratinocytes activated by *Malassezia* antigens also produce antimicrobial peptides but it is not known to what extent these are protective.¹⁸²

6.2 Activation of antigen presenting cells

Activation of antigen presenting cells has also been demonstrated *in vitro* using human-derived immature monocyte-derived dendritic cells (MDDCs), which are analogous to Langerhans' cells in the skin. These cells can take up whole *M. furfur* yeast cells and extracts, as well as recombinant *M. furfur* allergen 5 (Mal f 5)¹⁸³ Mala f 1¹⁸⁴ and *M. furfur* mannan. The internalisation was shown to occur via binding to the mannose receptor and pinocytosis. Subsequently, the MDDCs underwent maturation, indicated by up-regulation of CD83 expression and increase in expression of the co-stimulatory molecules CD80 and CD86. These mature dendritic cells are excellent antigen presenting cells and are capable of presenting peptides on MHC molecules to T cells.¹⁸⁵ Dendritic cells have also been shown to be activated by interaction between *Malassezia* antigens and various members of the C type lectin class of receptors such as Mincle, Dec-1 & 2, and Langerin.¹⁷⁵ This results in the production of pro-inflammatory cytokines such as IL-1, IL-6, IL-8 and TNF- α .¹⁷⁵ A recombinant Mala f 1 gene fragment upregulated the production of IL-6, TNF-Alpha and IL-10, but not IL-12, from human leukaemia-derived dendritic cells.¹⁸⁴ Interestingly, dendritic cells that have been stimulated by *Malassezia* antigens appear to be resistant to lysis by Natural Killer cells, a mechanism that likely favours survival of the cells in order to maintain antigen presentation.¹⁸⁶

6.3 T-lymphocyte mediated immune responses

T cell-mediated immunity is important in the prevention and recovery from fungal infections and healthy human individuals demonstrate cell mediated immune responses throughout life.¹⁸⁷ A deficiency in cell-mediated responses could therefore predispose the host to overgrowth of *Malassezia* organisms. Cell-mediated immune responses to *Malassezia* organisms have been investigated both in humans and dogs using assays such as leucocyte migration inhibition, peripheral blood mononuclear cell (PBMC) proliferation, immunohistochemistry, cytokine production, skin prick tests and atopy patch tests. *Malassezia* antigens and extracts have been shown to stimulate proliferation of PBMCs in a dose dependent manner in both humans¹⁸⁸ and dogs.^{189,190} Furthermore, a reduction in PBMC responses was seen in seborrhoeic basset hounds compared to healthy basset hounds,¹⁸⁹ although the role of this impaired response in the pathogenesis of *Malassezia* overgrowth in this breed is currently unknown.

Despite the possible role of T lymphocytes in protective immunity, there is evidence that these cells are involved in sensitisation of humans and dogs that become allergic to the yeasts. Basset hounds with *Malassezia* dermatitis usually show delayed rather than immediate intradermal test reactivity to *Malassezia* antigens¹⁹¹ although contact sensitization, as demonstrated by patch test reactivity and characterised histologically by infiltration with CD3+ lymphocytes and neutrophils, more closely correlates with disease status in this breed.¹⁹² In both atopic

humans and dogs, PBMC responses to *Malassezia* spp. are exaggerated. *Malassezia* antigens triggered significantly higher PBMC responses in atopic people compared to healthy individuals^{193–196} and this effect has also been demonstrated in atopic dogs.¹⁹⁰ In *P. orbiculare* [syn. *M. globosa*] patch test-positive atopic dermatitis patients, an infiltration of CD4⁺ T cells is seen at the patch test site,¹⁹⁷ and the expression of intercellular adhesion molecule (ICAM)-1 and human leucocyte antigen (HLA)-DR in the dermis of these patients was also up-regulated. Furthermore, in lesional atopic skin, the majority of the T cell clones that were reactive for *P. orbiculare* showed a Th2 or Th2/Th0 like cytokine profile¹⁹⁵ and atopic human patients that are sensitised to *Malassezia* yeasts typically show increased synthesis of the Th2-related cytokines IL-4, IL-5, IL-10 and IL-13 by *Pityrosporum* [*Malassezia*]-stimulated PBMCs.^{196,198,199} Taken together, these findings provide compelling evidence that T lymphocytes play a pivotal role in the generation of hypersensitivity reactions to *Malassezia* species in genetically susceptible individuals.

6.4 IgG, IgM and IgA responses to *Malassezia* yeasts

As would be expected in a typical immune response against an infectious agent, antibodies directed against antigens from *Malassezia* yeasts are produced in healthy humans and dogs throughout life. IgM, IgG and IgA antibodies against *Malassezia* species are present in both young and elderly people, but the amount of IgG and IgM tends to tail off with age corresponding with declining numbers of commensal yeasts.^{200–202} The *Malassezia*-specific IgA concentration was found to be relatively low in all age groups. In dogs, serum titres of *Malassezia*-specific IgG and IgA in seborrhoeic basset hounds with high cutaneous populations of *M. pachydermatis* and affected dogs of various breeds significantly exceeded those of healthy basset hounds and healthy beagle dogs.¹⁸⁹ Using Western immunoblotting to detect IgG responses in dogs to extracts of *M. pachydermatis*, four proteins of 219, 110, 71 and 42 kDa were shown to be recognised mainly by dogs with *Malassezia* dermatitis as compared to healthy dogs.²⁰³

In humans with atopic dermatitis, the *Malassezia*-specific IgG concentration in adults is no different to that found in healthy individuals.^{194,197} However, in young atopic patients aged between 16 and 21 years, significantly elevated *Malassezia*-specific IgG concentrations are found.^{86,204} This probably reflects increased exposure to the organisms through atopic skin and a tendency for IgG to follow IgE production. Despite this, no correlation has been found between *Malassezia*-specific serum IgG concentration and atopy patch test responses to the yeast in patients with atopic dermatitis.^{63,197} It is therefore considered that determination of *Malassezia*-specific IgG concentrations has little value in the diagnosis of *Malassezia* sensitization in atopic human patients.^{178,197} However, concentrations of IgG4, a subtype that is induced in Th2 responses, are correlated with IgE concentrations in atopic patients with sensitivity to *Malassezia sympodialis*.²⁰⁵

In atopic dogs with or without cytological evidence of *M. pachydermatis* overgrowth, there are significantly

higher serum titres of *Malassezia*-specific IgG than those seen in healthy dogs.²⁰⁶ However, there was no significant difference between atopic dogs with or without *Malassezia* overgrowth. By comparing the IgG response to *M. pachydermatis* antigens using western immunoblotting, a protein of 25 kDa was identified in the majority of atopic dogs with *Malassezia* dermatitis, but only a few atopic dogs without *Malassezia* overgrowth and none of the normal dogs, suggesting that this protein may have some clinical relevance in the pathogenesis of *Malassezia* hypersensitivity.²⁰⁷

In summary, it is clear that IgG responses to *Malassezia* yeasts are common in both healthy humans and dogs. This probably reflects exposure of the immune system to antigens produced by commensal organisms. However, enhanced IgG responses can be seen in dogs with *Malassezia* dermatitis and in humans and dogs with atopic dermatitis. The role of this IgG response in the pathogenesis of skin disease is currently unclear, both in humans and dogs. However, as overgrowth with *Malassezia* organisms does not appear to be a self-resolving condition, it seems likely that these antibodies are not protective. Alternatively, IgG antibodies could activate the complement system, as has been demonstrated with *Pityrosporum ovale* [*M. furfur*] and *P. orbiculare* [*M. globosa*],^{208,209} and exacerbate the inflammatory response. A final possibility is that IgG responses to the yeast are merely an epiphenomenon and neither contribute to, nor inhibit, the ongoing disease process. Further studies are therefore required to determine the precise role played by these antibodies in *Malassezia*-induced skin disease.

6.5 IgE responses to *Malassezia* yeasts

Increased concentrations of *Malassezia*-specific IgE are frequently present in atopic humans and dogs. Multiple studies have shown that IgE responses to *Malassezia* organisms are significantly higher in human patients with atopic dermatitis compared to those with other atopic diseases or healthy individuals.^{194,204,210–215} In human patients with atopic dermatitis of the head and neck, the clinical severity of the condition is significantly correlated with the concentration of anti *M. furfur* IgE.²¹⁶ Furthermore, IgE production by PBMCs stimulated with *Malassezia* extracts *in vitro* was significantly higher in radioallergosorbent test (RAST)⁺ atopic dermatitis patients compared with RAST⁻ atopic dermatitis patients or healthy controls.¹⁹⁸ This *Malassezia*-specific IgE has been found to correlate with the degree of response to *Malassezia* extracts in atopy patch tests at 48 h post-test in atopic dermatitis patients.¹⁹⁷

In humans, multiple proteins from *Malassezia* yeasts ranging in molecular size from 9–110 kDa have been characterised as major allergens in atopic dermatitis and a number have been sequenced and cloned, including Mal f 1–9 and Mal s 1–13.^{215,217–227} One particular allergen, Mala s 13, a thioredoxin enzyme, can cross-react with the human form of the enzyme, leading to the production of auto-reactive T cells that can sustain ongoing skin inflammation.²²⁸ A similar effect has been reported for Mala s 11, a manganese-dependent superoxide dismutase enzyme that is found in both yeast and human cells.¹⁷⁴

In dogs, concentrations of IgE antibodies to *M. pachydermatis* are significantly higher in atopic dogs than in healthy dogs or non-atopic dogs with *Malassezia* overgrowth.²⁰⁶ However, dogs with recurrent *Malassezia* otitis had similar concentrations of allergen-specific IgE to those with healthy ears, suggesting that hypersensitivity is not always involved in such infections.²²⁹ Using Western immunoblotting to characterise individual antigen responses, proteins with molecular weights of 45, 52, 56 and 63 kDa from *M. pachydermatis* have been demonstrated to be major allergens in atopic dogs with *Malassezia* overgrowth.²³⁰

These studies provide convincing evidence that proteins from *Malassezia* yeasts can act as allergens in dogs predisposed to the development of atopic dermatitis.

6.6 Mast cell responses

Studies have indicated that mast cells may be involved in innate immune responses against *Malassezia* spp. The interaction between Curdlan, a β -glucan component of the cell wall of *M. sympodialis*, and C-type lectin pattern recognition receptors (such as Dectin-1) expressed on the surface of human cutaneous mast cells, induced degranulation and augmented IgE-mediated granule exocytosis.²³¹ In other circumstances, fungal ligands may induce Dectin-1 mediated mast cell activation and production of chemokines and cytokines without degranulation.²³¹

In order to demonstrate full IgE-mediated hypersensitivity, it is necessary to document mast cell degranulation following allergen exposure. In humans, both intradermal tests (IDT) and skin prick tests (SPT) may show positive reactivity to *Malassezia* allergens in patients suffering from atopic diseases,²¹² whereas these tests are usually negative in healthy controls. Stronger reactions are typically seen in patients with generalised atopic dermatitis,^{193,204,212} or those with lesions predominantly on the head and neck.^{218,221,232} The SPT results have also been found to correlate with levels of *Malassezia*-specific IgE in the serum^{204,233} and with results of basophil histamine release tests²³² but not with the severity of atopic dermatitis.²³³

Positive IDT results to *Malassezia* extracts have also been reported in atopic dogs.¹⁹¹ Immediate hypersensitivity responses to intradermal injections of *M. pachydermatis* extracts at concentrations which caused no reaction in healthy dogs have been observed in atopic dogs with *Malassezia* dermatitis, although they were also seen in some atopic dogs without *Malassezia* dermatitis.²³⁴ Nevertheless, the reactivity to the extracts in atopic dogs with cytological evidence of *Malassezia* overgrowth was significantly higher than that in atopic dogs without.¹⁹¹ Additionally, positive immediate hypersensitivity reactions to extracts from *M. pachydermatis* using Prausnitz-Küstner tests have been demonstrated.²³⁵ Clinically normal dogs received pooled sera from atopic dogs with *Malassezia* dermatitis that were IDT positive to *Malassezia* extracts and serum from an atopic dog with *Malassezia* dermatitis exhibiting high levels of anti-*Malassezia* IgE on an ELISA assay. Positive IDT responses were observed in the recipients following subsequent injection of the yeast extract, indicating that anti-*Malassezia* IgE

antibodies are functional in Type I hypersensitivity reactions.²³⁵ As with intradermal testing to other allergens, there is reasonable agreement between the results of intradermal tests and IgE serology to yeast allergens, although it is possible to record a positive result in one test and a negative result in the other.²³⁶ The frequency of immediate hypersensitivity responses to *M. pachydermatis* extracts in non-atopic dogs with *Malassezia* dermatitis is low. One study investigating IDT reactivity to *M. pachydermatis* in eight healthy basset hounds, 17 basset hounds with *Malassezia* dermatitis and 19 healthy beagle dogs, reported that only two affected basset hounds and one healthy beagle dog showed immediate hypersensitivity reactions.²³⁷ Taken together, these findings suggest that mast cell mediated hypersensitivity responses to *M. pachydermatis* allergens may be involved in the pathogenesis and contribute to the clinical signs in many cases of cAD. As a result of this *Malassezia* allergens are now typically included in standard intradermal allergen tests and IgE serology, although, to date, there is relatively limited evidence of beneficial effects of allergen-specific immunotherapy against *M. pachydermatis* in dogs.²³⁸

6.7 Conclusions

Based on the above studies, the likely sequence of events leading to immune responses to *Malassezia* yeasts can be summarized as follows:

- 1 *Malassezia* species proliferating within the stratum corneum of dogs (and humans) produce numerous antigens and allergens.
- 2 These antigens penetrate to the living epidermis and activate keratinocytes, resulting in the production of antimicrobial peptides and alterations in cytokine expression.
- 3 *Malassezia*-derived antigens that permeate into and through the living epidermis are captured by epidermal Langerhans' cells and/or dermal dendritic antigen-presenting cells.
- 4 These cells then migrate to regional lymph nodes and present the antigen to a T lymphocyte via a major histocompatibility complex (MHC) class II molecule.
- 5 In cooperation with different cytokines, T helper (Th) 0 precursor cells differentiate into Th1 cells and/or Th2 cells. A cytokine environment dominated by IL-12 would favour Th1 cell development, whereas IL-4 and IL-13 would stimulate the development of Th2 cells.
- 6 T helper cells would activate B lymphocytes and stimulate them to differentiate into antibody-forming plasma cells. By secreting IL-2 and IFN- γ , Th1 cells would promote IgG production, whereas IL-4 and IL-13 from Th2 cells would promote immunoglobulin class switching to IgE.
- 7 The production of *Malassezia*-specific IgG antibodies could potentially provide a degree of protective immunity against *Malassezia* organisms. Alternatively, these antibodies might activate the complement system causing epidermal damage and inflammation.

- 8 The development of allergen-specific IgE antibodies could lead to sensitization of cutaneous mast cells. Subsequent exposure to *Malassezia* allergens could trigger the release of inflammatory mediators, resulting in a Type I hypersensitivity reaction.
- 9 Circulating populations of *Malassezia*-specific sensitised T-cells might mediate delayed and contact hypersensitivity in selected patients.

6.8 Implications for clinical diagnosis and therapy

- 1 A range of immunological hyper-responsiveness can be present in dogs with *Malassezia* dermatitis (none, immediate, delayed, contact). Tests for immediate hypersensitivity (serology, intradermal) are relatively accessible (although not standardised) whereas delayed reactivity following intradermal testing is assessed infrequently and patch testing is technically challenging in the clinical environment.
- 2 Serological and skin test reactivity is also seen in a proportion of unaffected dogs; thus immunological tests must be assessed in the context of clinical and cytological data; they should not be used as stand-alone 'diagnostic' tests.
- 3 It is intuitive that evidence of immediate, IgE-mediated or cellular hypersensitivity might indicate the need for rigorous antifungal therapy to minimize allergen challenge in the sensitized host, although this remains to be proven by controlled therapeutic studies.
- 4 Although evidence of immediate, IgE-mediated hypersensitivity provides a rationale for allergen-specific immunotherapy (AIT), to date, there is relatively limited evidence of beneficial effects of AIT against *M. pachydermatis* in dogs. More data is required before this can be systematically recommended.
- 5 Whilst some laboratories offer serological testing for IgG reactivity to *M. pachydermatis*, the clinical utility of this test is uncertain because there is no evidence of any diagnostic or therapeutic value.

7 Predisposing factors for development of *Malassezia* dermatitis

Overgrowth of commensal *Malassezia* yeasts may occur due to alterations of the skin's surface microclimate, leading to inflammatory skin disease.²³⁹ Primary diseases that cause increased moisture, altered surface lipids, and/or disruption of stratum corneum barrier function, or aberrant immune responses may encourage this secondary process of overgrowth.

7.1 The role of gender, age and breed

Gender and age do not appear to be consistently correlated with the presence of *Malassezia* dermatitis, but breed predilections in dogs have been described in several studies where cases were compared to the institutions' general hospital^{67,240,241} or diagnostic laboratory²⁴² populations. Breeds identified to be at increased risk by these studies include West Highland white terriers (WHWT), English setters, shih tzus, basset hounds,

American cocker spaniels, boxers, dachshunds, poodles and Australian silky terriers. Breeds with conformations that favour skin folds are also prone to infections at intertriginous anatomical sites. The basset hound and WHWT in particular demonstrate clinically distinctive conditions characterized by generalized seborrhoea (basset hound)^{98,145} or generalized, severely pruritic dermatitis with marked lichenification and hyperpigmentation.²⁴³ It is noteworthy that all of these breeds are recognized to be at increased risk for developing either atopic dermatitis or primary idiopathic seborrhoea. However, basset hounds in the UK that present with (an albeit relapsing) *M. pachydermatis*-associated seborrhoeic presentation typically respond dramatically to antimicrobial shampoo therapy with no residual clinical signs of atopic or seborrhoeic dermatitis.¹⁴⁵

Likewise, predisposed feline breeds have been recognized, although not through statistical analyses as compared to general hospital populations. Case-control studies in Devon rex cats and the sphynx breed, have demonstrated increased *Malassezia* counts as compared to domestic shorthaired cats.^{78,81,115,116} In these cases, *Malassezia* overgrowth is associated with the clinical finding of seborrhoeic skin; especially in the claw folds.⁷⁸

7.2 The role of cutaneous hypersensitivity disorders in the host

Pruritic inflammatory diseases such as atopic dermatitis may create microclimate changes due to scratching (disruption of barrier function), licking (added moisture) or increased production of sebum.¹⁰⁷ Despite the clinical observation that *Malassezia* overgrowth and atopic dermatitis commonly co-occur,^{107,244} studies have sometimes failed to demonstrate a clear statistical association between the two conditions.^{240,241} Nevertheless it is generally accepted that *M. pachydermatis* may increase the inflammation associated with cAD directly by induction of inflammatory cytokines from epidermal cells and indirectly by acting as an allergen^{234,239} (Section 6). Thus, a hypersensitivity response to *M. pachydermatis* might explain the discordance in the studies mentioned above since density of yeast on the skin's surface cannot be used as the sole determinant of its pathogenic effect.²³⁴ However, in a study where cAD was the predominant diagnosis for a group of dogs with inflammatory skin lesions, there was a statistically significant correlation between higher CADESI-03 scores and increased colony forming units of *M. pachydermatis* isolated by quantitative culture.¹⁰⁷ The range of epidermal barrier defects that might influence *Malassezia*-host interactions in cAD has been the subject of a detailed review.²³⁹ *Malassezia* spp. overgrowth has also been reported in series of cats with allergic skin disease.^{85,114}

7.3 The role of seborrhoeic dermatoses and aberrant cornification

Primary and secondary seborrhoeic conditions also favour proliferation of *Malassezia* spp. Seborrhoeic dermatoses in dogs have been statistically associated with significantly higher *M. pachydermatis* skin surface counts as compared to healthy dogs.^{98,245} Similar associations have been described in cats with seborrhoeic disorders.^{80,115} Endocrinopathies such as hypothyroidism and hyperadrenocorticism may cause secondary seborrhoea in dogs;

while no studies have demonstrated either disease to be an independent risk factor for *Malassezia* overgrowth, cases where an endocrinopathy and *Malassezia* dermatitis have occurred concurrently have been reported.^{240,241,246} In cats, no differences in *Malassezia* carriage were noted between healthy controls and cases with either hyperthyroidism or diabetes mellitus, using a contact plate technique for quantitative culture at several body sites; however, it should be noted that the cats with endocrinopathies in this study had no skin lesions at the time of sampling.⁸²

Malassezia overgrowth appears to be favoured by skin diseases with (assumedly) altered stratum corneum barrier function through aberrant cornification. Diseases of dogs characterized histopathologically by parakeratotic hyperkeratosis – such as zinc-responsive dermatosis and hepatocutaneous syndrome/superficial necrolytic dermatitis – have been anecdotally reported to promote yeast overgrowth (Section 10).²⁴⁷ The presence of *Malassezia* overgrowth is associated with pruritus in American bulldogs with autosomal recessive congenital ichthyosis caused by a single base deletion in the gene *NIPAL4*.^{248–250} In cats, a histological study of 550 skin biopsy cases identified *Malassezia* overgrowth most commonly with thymoma-associated dermatosis (TAD) and paraneoplastic alopecia (PNA) associated with internal neoplasia.⁸³ In TAD, parakeratosis is a common histopathological feature, while PNA presents either with absence of a stratum corneum or some degree of parakeratosis.⁸³ In one cat with TAD, resolution of *Malassezia* dermatitis was reported to occur after its thymoma was surgically excised.²⁵¹ It is important to recognize that these diseases are not typically pruritic unless *Malassezia* overgrowth is present. Feline facial acne, thought to represent an idiopathic disorder of follicular keratinization, may also result in *Malassezia* overgrowth.²⁵²

7.4 The role of climate

The skin surface presents a range of natural micro-climates and several ecological niches with different moisture and nutrient levels may be recognised.²⁵³ The eyes, ears, nares, oral cavity, lip fold, prepuce, vagina and anus provide microenvironments that are moist with secretions and constitute unique ecological niches (Section 4). The skin also presents gross topographical features that affect moisture and retain secretions such as the intertriginous zones and the interdigital spaces. It is from these areas that *Malassezia* overgrowth commonly develops. The external (macro-) environment may also play a role in predisposing dogs to *Malassezia* overgrowth. It is generally recognised that *Malassezia* dermatitis is more common in tropical climates and during warm, humid months in more temperate latitudes, in accordance with the concept that *Malassezia* yeasts inhabit a 'transitional mantel zone' that is influenced by both host skin and the animal's external environment.⁸⁷ Although not specifically studied in the dog, this factor is well-documented in human medicine.³³

7.5 Factors of uncertain importance

The role of immunosuppression as a risk factor for *Malassezia* overgrowth has been discussed anecdotally,⁷⁰ but

no studies have examined the immunosuppressed state as a risk factor for animals with active yeast infection. In cats without skin disease, retroviral infection was associated with increased density of *Malassezia* spp. isolation from the hair coat as compared to non-infected cats.²⁵⁴

Antibacterial therapy has not been reported to be an independent risk factor for development of *Malassezia* dermatitis in any published studies. However, a correlation between the onset of *Malassezia* dermatitis (or otitis) and the recent use of antibacterial drugs is sometimes observed by practitioners and could reflect a reduction in "competition" for micro-ecological resources as the bacterial population is reduced.²⁴¹ However, the opposite has also been noted for individual dogs, where yeast counts dropped following treatment with cefalexin.¹⁴⁶

7.6 'Idiopathic' cases

In a proportion of dogs and cats with *Malassezia* dermatitis, no concurrent disease or predisposing factors are identified.^{70,241} This is analogous to "idiopathic recurrent pyoderma" and likely reflects incomplete understanding of, and an inability to investigate and define in detail any impairment of, the complex co-ordinated innate and adaptive immune events that determine the outcome of skin colonisation by these yeasts (Section 6).

7.7 Conclusions

Dog breeds identified to be at increased risk of *Malassezia* dermatitis include West Highland white terriers (WHWT), English setters, shih tzus, basset hounds, American cocker spaniels, boxers, dachshunds, poodles and Australian silky terriers. Devon rex and sphynx cats are also predisposed. The presence of skin folds is a common risk-factor for localised disease. Dogs with *Malassezia* dermatitis often have concurrent hypersensitivity disorders, cornification defects or endocrinopathies. Cats without a breed predilection most often have an underlying hypersensitivity disorder, visceral neoplasia or other serious internal disease.

8 Quantification of *Malassezia* populations on canine and feline skin by cytology and culture

8.1 Background

The assessment of the presence and number of *Malassezia* species is an important step in the characterisation of the cutaneous ecosystem of dogs and cats in both health and disease. Studies utilising traditional cytological and cultural methods have clearly demonstrated that *Malassezia* yeasts are normal inhabitants of healthy canine and feline skin and mucosae (Section 4).^{58,65,73,81,94,104,255–257} It is also clear that *Malassezia* overgrowth is a feature of a variety of clinical presentations in dogs^{98,102,107,145,245,258} and cats.^{81,82,85,115,259} More recently developed molecular techniques have the advantage of being able to detect minority populations or organisms that cannot be cultivated using routine methods¹⁴⁸, an issue that hindered progress with the lipid-dependent *Malassezia* spp. for decades.⁴² The molecular microbiome approach has led to a marked expansion of the diversity of bacterial genera shown to inhabit skin.¹⁴⁸ The

Malassezia genus has retained its status as the dominant fungal inhabitant of this ecological niche in humans²⁶⁰, whereas dog and cat studies have shown a wider diversity of fungal genera, normally associated with an environmental source (Section 4). The relatively low abundance of *Malassezia* spp.^{117,118} likely reflects the detection of transient environmental visitors rather than permanent residents.¹⁴⁸

Researchers and clinicians have developed a range of semi-quantitative and quantitative methods for enumeration of yeasts in skin, some of which have important applications in veterinary clinical practice for routine diagnosis, assessment of response to therapy, and in research and development of novel therapeutic agents and formulations. However, it is important to recognise that each have limitations that affect the final count;²⁶¹ methods suitable for rapid assessment of *Malassezia* populations by veterinary practitioners 'on the clinic floor' are not necessarily optimal for scientific research. The relative lack of sensitivity of histopathology for detecting *Malassezia* spp. in the stratum corneum is discussed in Section 10.

8.2 Development and utility of skin sampling techniques for quantification of cutaneous *Malassezia* populations

Methods for microbiological assessment of skin populations have traditionally included impression (cytology using slides or tape; culture) and dispersal (primarily cup-scrub or swab-wash) methods.²⁶¹ Impression culture methods tend to under-estimate microbial populations whereas dispersal methods yield values closer to the true population.^{262,263} Cytological examination without impression (scrapings, swab samples) are more recent developments.

8.2.1 Impression cytology and related techniques

Development. Early studies primarily utilised cytological techniques as *Malassezia* dermatitis emerged as an important inflammatory disease of dogs. These included scraping methods,^{70,264} direct impression with glass slides,^{69,240} or slide preparations prepared by rolling swabs previously rubbed on the lesional skin.⁷⁰ One study elegantly described the utility of the direct application of vinyl adhesive tape in the assessment of cutaneous bacterial and fungal populations in human skin.²⁶⁵ A comparison of effectiveness of staining methods for detecting *Malassezia* cells in specimens from animals seems lacking, perhaps reflecting widespread satisfaction with a modified Wright-Giemsa stain ("Diff-Quik" [Harleco, NJ, USA] or generic equivalent) (Figure 3) that is likely to be available in the clinical area,^{67,266,267} although cotton-blue lactophenol⁶⁹ and May-Grunwald Giemsa¹⁰² stains have also been used.

Utility. Tape-stripping has gained wide acceptance in veterinary clinical practice as a rapid and versatile method for recovering stratum corneum cells and their attendant adherent microbes.²⁶⁸ It has also been used in a number of therapeutic studies,^{146,268} although these publications should be interpreted with due regard to the limitations of this method discussed below. Adhesive tape can be applied to deeply folded or recessed areas that are not readily accessible for direct slide application, often with

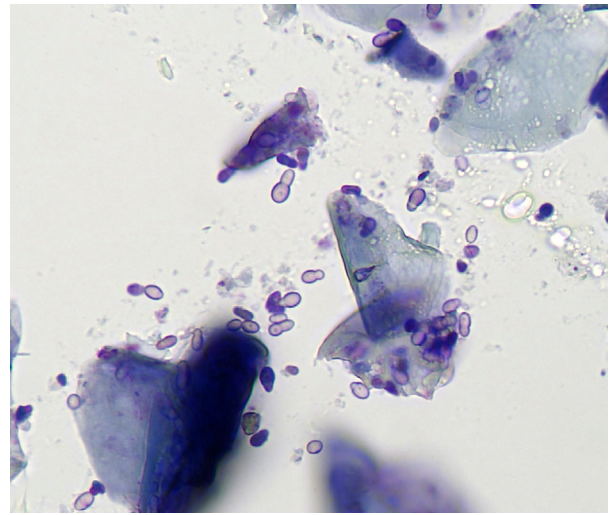


Figure 3. Tape-strip impression from the lip fold of a dog with *Malassezia pachydermatis* dermatitis.

Abundant ovoid to short cylindrical yeast cells with broad-based budding amongst squames; modified Wright-Giemsa stain ("Diff-Quik"), x50.

minimal animal restraint. The adhesive properties aid removal of skin surface material especially in erythematous lesions with limited exudation. By counting yeast cells in a certain number of microscopical fields in the tape-strip sample, a known area of skin surface is examined.²⁶⁶ Different brands of tape vary in their ability to resist staining procedures without crinkling or becoming opaque and a 'trial-and-error' approach is needed to identify suitable products from amongst those available locally. Scotch tape (3M, St. Paul, MN, USA) and Sellotape™ Diamond Clear (Henkel Ltd., Hemel Hempsted, UK) often work well.

8.2.2 Impression culture

Culture of impression samples obtained using contact plates,²⁶⁹ adhesive tape^{270–272} or Denman brushes²⁷³ for quantification of *Malassezia* spp. in skin was well described in human dermatology long before veterinarians became interested in this area, although contact plates have been used for the study of cutaneous bacteria in dogs.^{274–276} Squares of sterile carpet, popular for skin surface mycological sampling in France,²⁷⁷ have also been utilised for recovery of *Malassezia* spp. in dogs and cats.^{107,259,278}

Development. The contact plate technique was shown to be a convenient, rapid and inexpensive method for the quantitative culture of *M. pachydermatis* from canine skin.^{258,279} Comparable yeast counts were obtained in four serial applications of contact plates containing modified Dixon's agar to lesional canine skin. When incubated at 32°C, *M. pachydermatis* colony counts on contact plates after three and seven days of incubation were identical on both modified Dixon's agar and Sabouraud's dextrose agar (SDA), whereas day seven counts on both media were higher than day three counts when incubated at 26°C.²⁸⁰

Utility for dogs. The contact plate technique has been used to demonstrate significantly elevated groin

populations of *M. pachydermatis* in atopic dogs.²⁵⁸ In healthy dogs, increased frequencies of isolation and population sizes of *M. pachydermatis* were found in the lip and interdigital skin when compared with truncal sites.²⁵⁷ *Malassezia pachydermatis* populations varied between anatomical sites in healthy basset hounds, with higher populations on the pinnae when compared with the perineal area.²⁶⁷ Contact plate counts of *M. pachydermatis* were reduced by both oral ketoconazole and oral terbinafine in healthy basset hounds,²⁸¹ by climbazole shampoo in research beagle dogs,²⁸² and by chlorhexidine and climbazole wipes in a pilot study of five shar pei dogs.²⁸³

Utility for cats. Contact plate counts from the trunk were significantly higher in healthy Devon rex cats when compared to healthy domestic short-haired cats and Cornish rex cats; seborrhoeic Devon rex and sphynx cats had high yeast counts that exceeded those of the other groups.^{80,116} Contact plates were also used in two studies that assessed the beneficial therapeutic effects of oral itraconazole in cats with *Malassezia dermatitis*.^{86,284}

8.2.3 Dispersal methods – detergent (cup) scrub

Development. A detergent scrub technique using wash fluid comprising 0.075 M phosphate-buffered saline, pH 7.9 and 0.1 per cent Triton X-100, first reported for studies of the human cutaneous bacterial flora,²⁶² and subsequently in studies of cattle²⁶³ and dogs,^{285–287} is considered the 'gold standard' method for quantitative culture.^{261,268} The method was also used to quantify *Malassezia* organisms on human skin.^{288,289} In a series of development studies for quantifying *M. pachydermatis* on canine skin,²⁹⁰ counts of the yeast in suspension of pure cultures and in skin washings declined in contact with Triton X-100 and other detergents. Vortexing or manual or mechanical shaking of the samples yielded comparable counts. The technique was judged suitable for the quantitation of *M. pachydermatis* on canine skin provided samples were processed without delay and preferably within one hour of collection.

Utility. Detergent scrub sampling supported a genetic predisposition to *Malassezia* overgrowth in basset hounds by demonstrating high populations (compared to healthy mixed-breed dogs) in the axillae of healthy hounds and even higher numbers in the axillae of seborrhoeic basset hounds.⁹⁸ Detergent scrub counts were also used to evaluate and compare antimicrobial efficacy of shampoos in the treatment of seborrhoeic hounds.¹⁴⁵

8.2.4 Dispersal methods – swab wash

Development. Microbial populations recovered using conventional swabs can be quantified by dispersing organisms from the swab tip using solutions containing detergents; counts can be achieved by plating serial dilutions onto relevant culture media. This method was used previously in the quantification of staphylococci from porcine,²⁹¹ human,²⁹² and canine skin and/or mucosae.²⁹³ *Malassezia pachydermatis* counts did not vary significantly in each of four swabs applied serially to anus and external ear canal of healthy beagle dogs; dry swabs and moistened swabs had comparable efficiency at recovering the yeast.²⁷⁹ Yeast counts were comparable when swab tips held in wash fluid were shaken manually or vortexed for 30 s.

Utility. Using the swab wash technique, the anus was the most frequently colonised site in healthy mixed breed and beagle dogs,²⁵⁷ whereas *M. pachydermatis* was more frequently isolated in higher populations at nasal and buccal sites in both healthy and seborrhoeic basset hounds.⁹⁸ Swab-wash counts from the claw fold of sphynx cats and seborrhoeic Devon rex cats exceeded those of healthy domestic short haired, Cornish rex and Devon rex cats, whereas ear and anus populations were comparable.¹¹⁶

8.3 Comparison of methods

A number of investigators have evaluated the relative effectiveness of different sampling methods for *Malassezia* yeasts, primarily in dogs rather than cats. One early publication²⁴⁰ reported a subjective preference for direct impression using glass slides over use of cotton swabs, skin scraping and histopathology. Others found that both tape-strips and dry scrapes yielded high yeast counts from lesional skin whereas moistened swabs were much less efficient.²⁶⁶ Similarly, various authors have reported that swab cytology was inferior to superficial scraping,²⁹⁴ tape-stripping²⁹⁵ and conventional culture of swabs.⁸⁴ By contrast, *Malassezia* spp. yeasts and extracellular cocci were recovered in higher numbers from the dorsal claw fold (following skin eversion) by gentle scraping with the sharp point of a tooth pick, when compared with tape-stripping and direct impression using glass slides,²⁹⁶ likely reflecting enhanced cell exfoliation from the hard cuticle of the claw surface in this specialised site.

In a study of normal canine skin it was reported that the tape culture method was effective at recovering *Malassezia* but only low numbers of yeast cells were found in samples prepared by direct glass slide impression, skin scraping or cotton swab sampling.⁹⁴ *Malassezia pachydermatis* was more frequently detected in a group of dogs with chronic dermatitis using a tape culture technique when compared with conventional swabbing.²⁹⁷ Potential growth interference from volatile antimicrobial components of the tape should be evaluated when this cultural method is utilised.^{270,298}

Yeast counts on diseased skin (18 sites in six dogs) measured by using detergent scrubs and a contact plate technique were significantly correlated whereas counts obtained by the tape-strip technique from adjacent skin did not correlate with either quantitative cultural method.²⁹⁰ Varied results were reported in other studies where tape-strip counts and contact plate counts have been compared.^{258,267} Contact plate counts typically yield *M. pachydermatis* population densities 100-fold lower than those derived by the dispersal detergent scrub technique^{257,290} and yeast cell densities measured by tape-strip.^{267,290} Thus, the contact plate technique may have low sensitivity for yeast detection when true populations are very low, but may prove more efficient when yeast are more abundant such as in clinical cases or in selected breeds with high populations in healthy skin.

8.4 Culture media

In quantitative investigations of the skin flora, the culture medium is known to have significant effects on the counts of *Malassezia* yeasts derived from human

skin,^{269,289,299} prompting analogous canine studies. Amongst *Malassezia* spp., *M. pachydermatis* is the least fastidious and normally grows readily on routine media such as SDA,¹⁰⁶ although *M. pachydermatis* variants with more-exacting lipid requirements have been isolated.^{105,300,301}

In early qualitative studies, the addition of 1% Tween 80 to a dextrose/ yeast extract agar enhanced the isolation of *M. pachydermatis*.³⁰² Tween 80 was not needed for the selective and differential isolation of *M. pachydermatis* in the presence of peptone,³⁰³ now recognised as the essential lipid source for growth of that species on SDA.^{18,106} *Malassezia pachydermatis* was isolated from swab wash samples in comparable numbers after three and seven days of incubation at 32°C on each of five media; SDA, SDA plus 1% Tween 80, Ushijima's medium A, modified Dixon's agar and Leeming's medium.²⁸⁰ After three days of incubation, the colonies were most distinctive on modified Dixon's agar, forming buff-coloured domed colonies 1–1.3 mm in diameter that were readily distinguished from other cutaneous microbes; on other media the colonies were low convex. Colony counts on contact plates were significantly greater after incubation for seven days on SDA and modified Dixon's agar than after three days at 26°C, whereas three day and seven day counts were comparable at 32°C; this poor growth on SDA at 26°C was in accordance with previous^{53,304} and subsequent reports.²⁷⁸ Counts from swab-wash samples grown on SDA or modified Dixon's agar for four or seven days were comparable at 32 and 37°C. When compared with aerobic culture, an atmosphere of 5–10% carbon dioxide significantly increased the frequency of isolation and the colony counts on SDA but not modified Dixon's agar in swab-wash samples incubated at 37°C for seven days.²⁸⁰

One study compared *Malassezia* counts on SDA and modified Dixon's agar from swabs and carpet squares at 27 and 37°C.²⁷⁸ The frequencies of isolation were significantly higher on modified Dixon's agar at both temperatures after eight days of incubation; higher counts of larger colonies were cultivated on modified Dixon's agar.

To the best of the authors' knowledge, there are no reports of comparative studies on quantification of *Malassezia* spp. from feline skin. Although *M. pachydermatis* predominates on both healthy cats and cats with dermatitis, lipid-dependent species such as *M. sympodialis*,^{56,76} *M. globosa*,⁷⁶ *M. furfur*,⁷⁷ *M. nana*,^{79,116} and *M. slooffiae*^{80,82,116} are occasionally encountered. Modified Dixon's agar has proven suitable for the isolation of these species at 32°C over a seven day incubation period, whereas SDA does not support their growth.¹⁸

8.5 Recommendations for culture

Modified Dixon's agar is the preferred medium for the isolation and quantification for *M. pachydermatis* from canine skin in view of the relatively rapid growth of distinctive colonies and its potential for supporting the growth of lipid-dependent isolates; incubation should be aerobic at 32–37°C for at least three days. SDA (preferably supplemented with 1% Tween 80) is an alternative for dogs if modified Dixon's agar is unavailable, although occasional more-lipid dependent isolates will be overlooked with this medium; temperatures below 32°C

should be avoided and use of 5–10% carbon dioxide should be considered.

In cats, samples should be grown on modified Dixon's agar at 32–34°C aerobically; cultures should be systematically extended to at least seven days in case of presence of slower growing *Malassezia* spp. Temperatures in excess of 34°C must be avoided because of the potential to inhibit the growth of thermo-sensitive species such as *M. globosa* known to inhabit feline skin.¹⁸

8.6 Defining normal and abnormal populations of *Malassezia* spp. yeasts in the context of clinical reports

Veterinary clinicians in speciality clinical practice are accustomed to systematically evaluating *M. pachydermatis* populations in inflammatory skin lesions in the majority of their canine and feline patients, most often with cytology; they will frequently record "elevated populations" or "overgrowth" in their clinical records. When these observations are subject to critical scientific review (such as when case series or reports are submitted to journals for publication) problems arise because reviewers and editors tend to prefer objective confirmation of such claims. This has resulted in definitions of abnormal populations in terms of "more than XX yeast cells in YY oil-immersion (x100) fields".

It is important to appreciate that these definitions are likely arbitrary unless previous studies established the likely values obtained with the identical sampling method in that particular anatomical site in that particular breed of dog or cat. Marked variations in populations between anatomical sites within the same dog are routinely described; for example, contact plates may yield confluent growth from the lip region of healthy dogs whereas counts are routinely much lower in the axilla and groin.²⁵⁷

Breed variation is extreme in some circumstances, for example in basset hounds^{98,305} and Devon rex and sphynx cats.^{80,115,116} It is important to note that high populations can be recovered from clinically normal skin; using the 'gold standard' detergent scrub samples, population sizes in healthy and seborrhoeic basset hounds were shown to overlap.⁹⁸ "High" counts need not necessarily be clinically relevant in each case where they are detected.^{98,257} By contrast, "normal" or at least "lower" populations may be sufficient to exacerbate cutaneous inflammation in patients with immediate or delayed hypersensitivity responses.^{234,306,307} Ultimately, a commensal existence or cutaneous disease caused by *M. pachydermatis* involves complex interactions between the yeast and its' mammalian host that are not simply a result of achieving a particular number or density of yeast cells within the stratum corneum.

8.7 Conclusions: recommendations for skin sampling in dogs and cats

Routine cytological sampling of skin sites in the veterinary clinic is best achieved by light microscopical examination (50× or 100× oil objectives) of tape-strips or dry scrapes stained with modified Wright Giemsa stain ("Diff-Quik" or generic equivalents). Cytology using swabs is normally best restricted to use in the ear canal. Factors such as important variations in anatomical site, breed, sampling method and host immune status commonly thwart the

interpretation of the clinical significance of an observed population ("XX yeasts in YY fields"); trial therapy is routinely required to establish this (Sections 8.5 and 14.1–3).

A single report indicates that the sharp end of a tooth pick is the preferred method for sampling the dorsal claw fold in dogs.

Routine cultures provide primarily qualitative data on presence/absence of yeast, although "heavy" growth on primary isolation plates likely indicates a high population.

Contact plates allow convenient, rapid and inexpensive quantitative culturing of *M. pachydermatis* from canine and feline skin; they are suitable for both diagnostic and research purposes. Optimally sized plates for cats and dogs (typically 18–27 mm diameter depending on site sampled) containing the preferred medium (modified Dixon's agar) are not available commercially but are readily custom-made in mycology laboratories that are accustomed to preparing their own media.

Detergent scrub sampling is the 'gold standard' method for quantitative culture, although it is more suited to a research rather than diagnostic environment because it is suitable for only relatively flat skin on co-operative patients and rapid sample processing is required. This is the optimal technique for mycological assessment in therapeutic product development.

9 Diagnostic methods: molecular and mass spectrometry identification of yeasts in culture and skin

The application of molecular biological techniques has underpinned the radical transformation of the taxonomy of the genus *Malassezia* over the last 30 years with an expansion from two to 18 recognised species (Section 2).^{8,53} This section briefly reviews some of the more commonly reported molecular and mass spectrometry techniques that may be encountered in the veterinary literature on *Malassezia* species.

9.1 Electrophoretic karyotyping

Electrophoretic karyotyping involves the separation of intact chromosomal DNA according to its size on an agarose gel, generating specific banding patterns dependent upon the number and size of chromosomes.^{9,308} This technique differentiates between *Malassezia* species, but not between genotypes within each species.^{56,76,309} The ready availability of sequence-based methods has largely superseded this method in yeast identification.

9.2 Ribosomal RNA gene sequencing

Ribosomal RNA gene sequences have proven attractive targets for molecular fungal taxonomy on account of the presence of multiple copies in the genome and their tendency to have combinations of highly-conserved sequences that may be recognised by pan-fungal PCR primers, separated by highly varied species-specific or genotype-specific domains. Amongst these, the D1/D2 domain of the 26S rRNA and the internal transcribed spacer (ITS) regions have been frequently used in the identification and phylogenetic studies of *Malassezia* species (Figures S1 and S2).^{26–28,32,301,310–312} Partial sequencing of the 26S rRNA of one hundred *M.*

pachydermatis isolates identified seven sequence types, named sequevars (Ia–Ig); some of these variants seem to be host-specific for dog, ferrets and rhinoceros.³⁰⁰

Marked sequence diversity of the intergenic spacer (IGS)(Figure S1 and S2) of *M. pachydermatis* isolated from dogs and cats enabled identification of three major groups (1, 2, 3) with 10 subtypes (1A, 1B, 1C, 1D, 2A, 2B, 3A, 3B, 3C and 3D).³¹³ In Japan, Korea and Taiwan, isolates of *M. pachydermatis* of subtype 3D were obtained more frequently from cAD skin lesions than from healthy canine skin.³¹⁴ Moreover, subtype-3D strains isolated from atopic dermatitis skin produced higher amounts of phospholipase A2 than did strains of other genotypes, supporting the hypothesis that the pathogenicity of this yeast is associated with the production of high levels of phospholipase A2.¹⁵⁷ By contrast, lack of sequence diversity in the IGS region of *M. nana* isolates,¹¹¹ and in the β -tubulin gene and microsatellite profiles¹¹² indicate that a particular *M. nana* genotype predominates in cats.

9.3 Chitin synthase 2 and β -tubulin genes

Amplification of the *chitin synthase 2* (*CHS2*) gene in seven *Malassezia* species yielded an ~620 bp fragment with 95% sequence homology between the species, although phylogenetic analyses indicated that each species was genetically distinct.³⁴ Limited genetic variability is seen in the *CHS2* gene amongst *M. pachydermatis* isolates from dogs in previous studies,^{315,316} although wider variation was observed in another study.⁵⁷ Partial sequencing of the β -tubulin gene in *Malassezia* provides a further opportunity for species and genotype differentiation.^{35,112,317}

9.4 Multilocus PCR approaches

Genotypic approaches involving analyses of sequences obtained from multiple loci on the *Malassezia* genome, such as combined analyses of D1/D2, ITS, CHS2 and β -tubulin sequences, has proven to be a powerful tool in the epidemiological assessment of the intraspecific variations and adaptation of these particular genotypes to specific hosts.^{35,57,301,318}

9.5 Random amplification of polymorphic DNA

As the name suggests, random amplification of polymorphic DNA (RAPD) is a PCR-based method where short primers bind to random sites on the yeast genome to produce fragments that create specific banding patterns on electrophoresis. Whilst reproducibility is sometimes challenging, it is regarded as a useful epidemiological tool amongst *Malassezia* species.⁸⁸ One study reported that RAPD analysis of *M. pachydermatis* indicated the existence of four different genotypes (genotype 1 to 4), with the genotype-1 strains producing the highest amounts of biofilm and phospholipase activity.¹⁵⁹ Moreover, the study also reported that the inflammatory response induced by *M. pachydermatis* strains in immortalized human keratinocytes (HaCat cells) was significantly higher in cells co-cultured with strain of genotypes 1 or 2.¹⁵⁹ Conversely, cells infected with strains of genotype 3 or 4 did not significantly induce expression of TLR-2 and cytokines; overall these data further suggest a possible association between genotype and virulence factors expressed by *M. pachydermatis* strains.

9.6 Next generation sequencing and the microbiome

Methods based on next generation sequencing (NGS) have allowed a better characterization of the complex microbial communities occurring on the skin and made it possible to detect *Malassezia* species that would otherwise be missed using culture based methods (Section 4.4).

9.7 Multiplex PCR

A multiplex PCR method that utilized multiple hybridization probes for six *Malassezia* species, including *M. pachydermatis*, was reported to provide sensitive and rapid identification of *Malassezia* DNA in skin swab samples from both animals and humans.³¹⁹

9.8 MALDI-TOF mass spectrometry

Matrix assisted laser desorption ionization-time of flight mass spectrometry (MALDI-TOF MS) has emerged as a tool for identification of microbial cells or cell extracts.³²⁰ The method is rapid and sensitive, although identification of isolates is possible only if the spectral database contains fingerprints of the relevant species and strains. Mass spectrometry has also been utilised for the identification of *Malassezia* yeasts isolated from cases in three French university hospitals.³⁶ A MALDI-TOF database of main mass spectra has been developed to allow the rapid identification of 14 *Malassezia* species (Section 2).³⁷

9.9 Conclusions

Molecular techniques are pivotal in the accurate identification of many of the currently recognised *Malassezia* species, with the usual exception of *M. pachydermatis* (which is readily distinguished from the other species by growth on Sabouraud's dextrose agar). In particular, sequencing of D1/D2 domain of the large subunit of the *rRNA* gene, ITS, IGS, *CHS2* and *β -tubulin* genes or regions allows for accurate identification of species and recognition of genotypes that may have relevance for host-adaptation and virulence. Microbiome studies utilising next-generation sequencing have the potential to re-define the microbial ecology of mammalian skin. Multiplex PCR and MALDI-TOF MS hold promise for rapid and specific identification of *Malassezia* from skin and culture specimens, respectively.

10 Histopathological features of canine and feline *Malassezia* dermatitis

10.1 Background

The histopathological features in skin biopsy specimens from lesions of *Malassezia* infection in dogs and cats commonly represent an amalgamation of features reflecting both the host response to the yeast as well as the concurrent, underlying disease. Preparation of the skin prior to biopsy and/or the ready loss of surface scale and yeasts during histological processing results in the number of yeasts observed by microscopy to be of questionable interpretative pathological significance. The issue of yeast number is compounded by the potential for hypersensitivity responses to *Malassezia* allergens to exaggerate the immunological reaction out of proportion to the population density of the yeast (see Section 6). Taken together, a

diagnosis of *Malassezia* dermatitis cannot be made by histopathology alone; it is more realistic to limit expectations of histopathology to providing evidence of a consistent inflammatory process and/or indication of the nature of an underlying predisposing disorder. In routine cases, skin populations of the yeast are best assessed by cytology or quantitative culture (Section 8). In some cases, histopathological approaches might be best employed after the yeast has been removed by appropriate therapy to enhance the characterisation of underlying disease.

10.2 Experimental studies

Cutaneous responses to the application of viable and killed *Malassezia* have been assessed both clinically and histologically in laboratory animals (guinea pigs, mice, rabbits) and humans, primarily with "lipid-dependent" *Malassezia* species isolated from humans (whose nomenclature pre-dates current revised taxonomy) applied under occlusion.^{321–324} Lesions generally comprised focal areas of scaling that most often resolved without treatment upon discontinuation of inoculation and were characterised histologically by yeast cells or hyphae in the stratum corneum, variable epidermal hyperplasia and superficial dermal inflammation with granulocytes and lymphocytes. Interestingly, Swiss white mice developed skin lesions whereas the nude (nu/nu) mouse, the hairless mice and nude rats did not.³²¹ Inoculation of suspensions of *M. pachydermatis* into the middle ear and dermis of immunosuppressed mice led to transient infection that resolved within 21 days.³²⁵

In laboratory beagle dogs application of *M. pachydermatis* was associated with epidermal hyperplasia, occasionally with parakeratosis, superficial perivascular dermal inflammation with primarily neutrophils and lymphocytes, and sometimes mast cells (but not eosinophils); features were more severe at sites that were occluded.¹⁷⁶ Histological changes markedly reduced within seven days of withdrawal of yeast challenge.

10.3 Canine *Malassezia* dermatitis

Histopathologically, canine *Malassezia* dermatitis presents with variable but often marked hyperkeratosis and multifocal parakeratotic hyperkeratosis with the characteristic budding, bottle-shaped yeasts and often cocci (if not lost during processing) over an irregular spongiotic epidermal hyperplasia that extends to the follicular infundibula, see reviews.^{83,326} Exocytosis of lymphocytes is a regular feature and neutrophilic or eosinophilic exocytosis may create epidermal microabscesses. Mast cell exocytosis is rare but a linear array of mast cells at the dermo-epidermal junction is not infrequent. Pigmentary incontinence is occasionally observed. The follicular ostia and infundibulae may be dilated with hyperkeratosis, occasional focal parakeratosis and yeast cells, with variable cocci bacteria. The superficial dermis has variable oedema with interstitial and perivascular inflammation of lymphocytes (usually the dominant cell type), plasma cells, histiocytes, neutrophils and eosinophils.

As mentioned above, it is important to recognise that yeast cells are not always observed; *Malassezia* cells were absent in 23 out of 86 cases in one study.²⁴² The follicular ostia/ infundibulae may be the best place to find

yeast cells when numbers are low. Whilst visible in haematoxylin and eosin stained slides, periodic acid-Schiff or Grocott's-Gomori methenamine silver stains accentuate the presence of the yeast.

Authors in one study²⁴² proposed standardized histological criteria for the 'presumptive' or final histopathological diagnosis of '*Malassezia* dermatitis' comprising:

- 1 pronounced irregular epidermal and infundibular hyperplasia;
- 2 prominent epidermal and infundibular parakeratotic hyperkeratosis;
- 3 diffuse epidermal and infundibular intercellular oedema (spongiosis);
- 4 diffuse epidermal and infundibular lymphocytic exocytosis;
- 5 superficial perivascular to interstitial dermatitis wherein lymphocytes are a prominent inflammatory cell type.
- 6 presence of unipolar budding yeast in the surface and/or infundibular keratin.

In the case of absence of budding yeasts, those authors²⁴² regarded the histopathological diagnosis as "presumptive" provided the first five criteria were fulfilled. Unfortunately, similar features may be observed in skin biopsies from lesional skin in dogs with cAD,³²⁷ a disease whose signs may mimic or complicate those of canine *Malassezia* dermatitis.³²⁸ Features more supportive of *Malassezia* dermatitis include scalloping of epidermal and follicular margins, eosinophilic pustules and diffuse lymphocytic exocytosis, but none of these are pathognomonic.³²⁶

10.4 Feline *Malassezia* dermatitis

The histopathological features associated with *Malassezia* dermatitis in cats are poorly defined although hyperkeratosis and irregular epidermal hyperplasia have been observed in association with abundant yeasts in the stratum corneum, analogous to canine features.²⁵⁹ The lack of description of the histopathology associated with these yeast in allergic and seborrhoeic cats that are otherwise healthy reflects infrequent biopsy sampling in cases more readily assessed by cytological techniques or culture.⁸⁵ By contrast, more reports are available in cats with generalised infections that are often associated with visceral neoplasia or other serious internal diseases (Table S3).⁸³

10.5 Other conditions where *Malassezia* yeasts may be observed histologically

Malassezia yeasts may proliferate opportunistically in response to skin disease and it is therefore not surprising that they may be observed in the stratum corneum in a variety of conditions. According to a standard textbook,³²⁶ *Malassezia* may feature in cases of bacterial intertrigo, feline hypersensitivity reactions, acrodermatitis of bull terrier dogs, atopic dermatitis, congenital follicular parakeratosis, facial dermatitis of Persian and Himalayan cats, familial paw pad hyperkeratosis, feline acne, feline paraneoplastic alopecia, feline thymoma-associated exfoliative dermatitis, female hyperoestrogenism, food allergy, hypothyroidism, ichthyosis, interdigital furunculosis, mucinosis, nasodigital hyperkeratosis, sarcoptic mange,

seborrhoeic dermatitis, Sertoli cell tumour-associated skin disease, superficial necrolytic dermatitis and zinc-responsive dermatosis (Table S4).

10.6 Conclusions

A diagnosis of *Malassezia* dermatitis cannot be made by histopathology alone. Histopathological features in dogs often comprise hyperkeratosis or parakeratosis, irregular epidermal hyperplasia and spongiosis that extends to hair follicle infundibulae, lymphocyte and granulocyte exocytosis, and a mixed, predominately lymphocytic, superficial perivascular or interstitial infiltrate with variable superficial dermal oedema. Yeast cells may or may not be observed in surface or infundibular stratum corneum (cytology or quantitative culture are preferable for assessment of populations). In cats, histopathological features vary markedly according to the nature of the underlying disorder.

11 Antifungal susceptibility testing and resistance

11.1 Introduction

Antifungal chemotherapy is widely used in the treatment of a range of clinical presentations in both humans and animals that are attributable to cutaneous *Malassezia*. Previous reports have highlighted varied *in vitro* drug susceptibility results amongst the different species and within genotypes of selected species.^{329,330} The need for surveillance of antimicrobial resistance (AMR) in general has increased in parallel with the emergence of AMR as a significant threat in both human medicine and animal health. This section reviews literature relevant to *Malassezia* spp. and identifies areas for future development.

11.2 Methods

The susceptibility test is critical for the selection of treatment strategy and the control of drug-resistant pathogens and in circumstances where the organism's susceptibility cannot be reliably predicted by its' identity. In 2008, the Clinical and Laboratory Standards Institute published the most recent document (CLSI M27-A3) in its' series of reference standards for susceptibility testing of yeasts.³³¹ However, these focused on invasive human pathogens such as *Candida* and *Cryptococcus* spp. but *M. pachydermatis* does not exhibit sufficient growth in the standard defined (and lipid-free) RPMI 1640 medium to permit use of the reference method for this species. The European Committee on Antimicrobial Susceptibility Testing (EUCAST) analogous reference susceptibility test for pathogenic yeasts and moulds³³² also specified use of an RPMI-1640 based culture medium that is unsuitable for *Malassezia* spp. Establishment of reference susceptibility tests for *M. pachydermatis* may ultimately depend on work by organisations such as the International Society for Human and Medical Mycology (ISHAM) working groups or the Veterinary Committee on Antimicrobial Susceptibility Testing (VetCAST), a subcommittee of EUCAST. In the absence of standard methods appropriate for *M. pachydermatis* the CLSI M27-A2 and A3 protocols have been adapted by various modifications of the process (Table S5).^{329,330,333-336} Technical specifics were usefully reviewed in detail, including a discussion of the

effects of medium and conditions of incubation, lipid supplementation, inoculum preparation, end-point determination and quality control aspects.³³⁷

Modified Etest protocols and conventional disc diffusion (CLSI M44-A) have also been used to determine the *in vitro* susceptibility of *M. pachydermatis* (Tables S5 and S6); tests of this type are more suited to routine diagnostic use than broth dilution methods.^{329,333,338} The CLSI-recommended medium (Mueller-Hinton agar supplemented with glucose and methylene blue) optimally supports the growth of *M. pachydermatis* provided the inoculum is incubated with a lipid source (Tween 40 or 80); agar diffusion using clotrimazole and miconazole discs on this agar yielded values that correlated with MIC determined by broth dilution.³³⁹ Etest, a commercially-available manual *in vitro* diagnostic method that utilizes a plastic strip with a predefined gradient of antimicrobial agent, was used to establish MIC values for ketoconazole and itraconazole that reportedly correlated well with those obtained using a broth dilution method.³³⁰ One limitation is that strips are not available for all antifungal agents used in dogs and cats.

11.3 Breakpoints: clinical versus epidemiological

A breakpoint is defined by EUCAST as “specific values of parameters such as minimum inhibitory concentrations (MICs) or inhibition zone diameters on the basis of which microbes can be assigned to the clinical categories “susceptible (sensitive)”, “intermediate” and “resistant”.”³³² There is scope for confusion around use of the term breakpoint. “Clinical breakpoints” indicate to the clinician the likelihood of therapeutic success when using a particular antimicrobial against an infectious agent. “Epidemiological cut-off values” (ECOFFs) (syn. epidemiological or microbiological breakpoints) represent the highest acceptable MIC value of the wild-type microbial populations with no acquired phenotypically detectable resistance mechanism³⁴⁰; it is important to note that this might not be clinically relevant if the MIC is still below that achievable with the drug at any given site of infection. Unfortunately, interpretive breakpoints for antifungal susceptibility testing of *Malassezia* species are not yet available; thus, any classification of isolates into susceptible, intermediate and resistant categories remains speculative. This may be especially challenging in the context of topical therapy where high local concentrations are often achieved.³⁴¹ Review of existing literature on *M. pachydermatis* susceptibility testing suggest that, in some cases, previous use of the term “resistant” would be best regarded as an ECOFF rather than a clinical breakpoint^{330,342} although further studies are required to confirm this hypothesis.

11.4 Antifungal drug susceptibility testing in *Malassezia* species

11.4.1 Azole antifungal drugs

Imidazoles such as clotrimazole, climbazole and miconazole are used topically (most commonly in otic products, creams or shampoos) although ketoconazole and its triazole derivative itraconazole are widely available for oral use in dogs and cats. Posaconazole, a triazole structurally similar to itraconazole, is used orally or intravenously for

the treatment of invasive mycoses in immunocompromised humans,³⁴³ and topically in dogs with *Malassezia* otitis. Clinical efficacy with these products corresponds to multiple, systematic reports of low MICs *in vitro* with drugs of this class,^{329,330,334,344} with the exception of fluconazole (see below).

11.4.2 Terbinafine

Terbinafine is a synthetic allylamine derivative that inhibits fungal ergosterol biosynthesis at the point of squalene epoxidation. Terbinafine was first shown to have activity *in vitro* against *Malassezia* spp. more than 30 years ago,³⁴⁵ although in the same study terbinafine activity was 20–800 times greater amongst a range of dermatophytes. Subsequent to conflicting reports of efficacy using topical versus oral dosing in human pityriasis versicolor, *in vitro* studies showed lower MICs in isolates of *M. sympodialis* that correlated with efficacy of oral dosing; higher MICs in *M. globosa*, *M. restricta*, *M. slooffiae* and *M. furfur* sensu stricto³⁴⁶ were associated with better responses to the higher concentrations achieved by topical therapy.³⁴⁷ These species-related differential susceptibilities were confirmed in a subsequent study, with *M. sympodialis* and *M. pachydermatis* showing greatest susceptibility amongst examples of relative tolerance amongst other *Malassezia* species.³⁴⁸

Further studies in collections of field isolates of *M. pachydermatis* have routinely indicated susceptibility at concentrations similar to those obtained with azole antifungal drugs. In a study of 24 *M. pachydermatis* isolates (urea broth dilution), mean MIC values of terbinafine were favourably comparable to those of itraconazole, although ranges or MIC₉₀ values were not reported.³⁴⁹ Similar activity was found (supplemented RPMI 1640 medium) with a single *M. pachydermatis* strain.³²⁹ In a study of 62 canine derived *M. pachydermatis* strains (Christensen’s urea broth, supplemented RPMI 1640), terbinafine was superior (based on MIC₉₀) to fluconazole by six two-fold dilutions but inferior to ketoconazole and itraconazole by three and five dilutions respectively.³³⁴ These values were barely exceeded in a pharmacokinetic study of skin concentrations achieved after oral dosing at 30 mg/kg sid.³⁵⁰ In another study (Sabouraud’s broth with 1% Tween 80) of 216 colonies of *M. pachydermatis* obtained from 28 dogs with otitis (n = 25) or dermatitis (n = 3), terbinafine was superior (based on MIC₉₀) to fluconazole by five two-fold dilutions but inferior to ketoconazole and itraconazole by one and four two-fold dilutions respectively.³³⁶ A similar relationship between terbinafine and ketoconazole susceptibility was noted in a study (supplemented Sabouraud’s broth) of 51 *M. pachydermatis* strains from canine ears.³⁵¹

11.4.3 Nystatin

The polyene cyclic macrolides, amphotericin B and nystatin, were amongst the earliest broad-spectrum antifungals introduced for clinical use.³⁵² The potential toxicity of amphotericin B generally limits its use in veterinary medicine to serious progressive or disseminated systemic mycoses, whereas nystatin is active when applied topically.³⁵³ Its mode of action is via altered cell membrane permeability mediated by preferential binding to ergosterol. These drugs were regarded as reference agents in

early studies of *M. pachydermatis* susceptibility to azoles because of well-established activity against the genus,³⁵⁴ although polyene-resistant strains have been induced *in vitro* by exposure to mutagen (N-methyl-N'-nitrosoguanidine) or UV irradiation.³⁵⁵

Wild type *M. pachydermatis* strains appear routinely susceptible to nystatin, although higher MICs (MIC₉₀ increased by a single two-fold dilution) have been reported amongst isolates obtained from dogs with skin disease when compared to isolates from healthy dogs (reportedly RPM11640).³⁴⁴ In a study of 51 strains from canine ears (supplemented Sabouraud's broth), nystatin was inferior to ketoconazole and terbinafine by seven and four two-fold dilutions, respectively.³⁵¹

11.4.4 Chlorhexidine

Previous studies of the activity of chlorhexidine against *M. pachydermatis* have primarily utilized dilutions of commercial products rather than conventional reference methods with the drug in its' pure form.^{356–359} Although most of these studies have evaluated very small numbers of isolates, a common theme is that *M. pachydermatis* is typically susceptible to dilutions of chlorhexidine products, in accordance with reports of clinical efficacy. To the best of the authors' knowledge, reduced susceptibility to chlorhexidine *in vitro* has not been reported.

11.4.5 Gentamicin and other aminoglycosides

Gentamicin is an aminoglycoside antibiotic with activity against many aerobic Gram-positive and negative bacteria, commonly formulated in polypharmacy otic products for dogs. Whilst gentamicin has been used as an inhibitor of bacterial growth in cultures of *M. pachydermatis* from ear swabs from laboratory dogs with high bacterial colonisation²⁸⁰, a subsequent report indicated that 20 of 20 isolates were susceptible to high concentrations *in vitro*.³⁶⁰ Further studies (Sabourauds agar, Christensen's urea broth with Tween 40 & 80) have shown a wide variation in effect, with MICs' of gentamicin ranging from 1.0 to >150 µg/mL.^{361,362} Netilmicin, tobramycin and framycetin also have variable but often high activity against *M. pachydermatis*.³⁶³ These studies indicate that gentamicin might not be an optimal drug, for suppression of bacterial growth, in culture media intended for the primary isolation of *M. pachydermatis* and that further studies are warranted. The extent of any clinical benefit of anti-*Malassezia* activity from gentamicin in otic formulations used in canine otitis externa requires further assessment.

11.4.6 Other drugs

A small number of publications report activity *in vitro* of other agents against *Malassezia* spp. These include plant-derived substances such as Blad-containing oligomer (an antifungal agent approved for agricultural use);^{364,365} beta-thujaplicin,³⁵¹ a honey-based gel,³⁶⁶ kanuka and manuka³⁶⁷ and other plant-derived essential oils;³⁶⁸ agents primarily used in the topical treatment of human dandruff or seborrhoeic dermatitis (selenium sulphide, zinc pyrithione, ciclopiroxolamine,³⁶⁹ rilopirox³⁷⁰) and

povidone-iodine.³⁷¹ The calcineurin inhibitors (tacrolimus and pimecrolimus) have activity *in vitro* against human-associated *Malassezia* yeasts.³⁷² The clinical relevance of these observations for canine and feline infections requires further assessment.

11.4.7 Combinations of antifungal drugs

Combining antifungal drugs might potentiate their efficacy, reduce the selection pressure for resistance, reduce side effects if lower doses can be used and achieve clinical efficacy when monotherapy is ineffective.^{280,373} In a study of 30 *M. pachydermatis* isolates from canine otitis externa, primarily indifferent and often divergent interactions were observed between azoles and nystatin, terbinafine and caspofungin, although 55% (16 of 30) of isolates showed a synergistic interaction between caspofungin and itraconazole or fluconazole.³⁷³ By contrast, amphotericin B antagonised the activity of itraconazole, but not fluconazole or posaconazole, in approximately 55% of 30 otic isolates of *M. pachydermatis* in a broth micro-dilution checkerboard system.³⁷⁴ An additive interaction between fluconazole and calcineurin inhibitors against *M. globosa* and *M. restricta* is mediated by the immunophilin gene FKBP12.¹³¹

11.5 Reports of reduced susceptibility to antifungal drugs amongst *Malassezia* yeasts

11.5.1 Selecting for resistance in the laboratory

In a study of 10 selected isolates of *M. pachydermatis* from canine ears (supplemented Sabouraud's broth), terbinafine MIC₅₀ increased by three two-fold dilutions when sub-cultured 30 times in Sabouraud's broth containing terbinafine at concentrations close to the original MIC.³⁵¹ Similarly, nystatin MIC₅₀ increased by a single two-fold dilution when sub-cultured in the same way and ketoconazole MIC₅₀ increased by four two-fold dilutions. From work in *Malassezia* and other pathogens, reduced susceptibility to azoles may be caused by reduced affinity due to alterations in the drug target enzyme,³⁷⁵ by increased expression of the target gene (*ERG11*) encoding this enzyme, or by increased efflux by overexpression of genes encoding membrane transport proteins of the ABC transporter (*CDR1/CDR2*) or the major facilitator (*MDR1*) superfamilies.³⁵² Induction of high fluconazole MICs in 30 strains of *M. pachydermatis* by prolonged exposure was associated with elevated MICs to other azoles, suggesting that the molecular basis for these effects may in some cases confer cross-resistance to this drug class.³⁷⁶ Further studies are needed to define the molecular genetics of the reduced susceptibility to azoles, terbinafine and nystatin induced in *M. pachydermatis* by laboratory exposure at sub-inhibitory drug concentrations and any implications for long-term drug use in clinical practice.

11.5.2 Studies of field isolates

Malassezia spp. are reportedly not susceptible to echinocandins and griseofulvin.³⁷⁷ The inherently lower antifungal potency of the triazole, fluconazole, is largely compensated by its excellent pharmacokinetic properties

for deep-seated infections of humans.³⁵² Amongst collections of *M. pachydermatis*, fluconazole consistently returns significantly higher MICs when compared with other clinically relevant imidazoles and triazoles,^{335,336,369,378} leading to questionable predicted clinical utility of this agent in dogs and cats, pending development of clinical breakpoints and further clinical studies.³⁷⁹

In 2010 a study reported the first itraconazole and ketoconazole "resistant" isolate of *M. pachydermatis*, originating from canine seborrhoeic dermatitis.³³³ Subsequently, it was reported that Italian clinical isolates of *M. pachydermatis* from canine skin lesions had low susceptibility to azoles compared with those from normal canine skin.³³⁴ Another study expressed concern about the phenomenon in the worldwide context, given that secondary infections with *M. pachydermatis* in cAD are frequently treated using azole-containing shampoos.³³⁸ These authors investigated azole (itraconazole and ketoconazole) susceptibility amongst *M. pachydermatis* isolates from cAD cases in East Asia over a two year period (2010 and 2011) by Etest using Sabouraud's dextrose agar supplemented with 0.5% Tween 40.³³⁸ MICs amongst isolates from cAD isolates were significantly higher than the isolates from healthy dogs, in parallel to studies of isolates from healthy and seborrhoeic dogs from the same region.³⁸⁰ Treatment failure in a dog with idiopathic *M. pachydermatis* dermatitis that had received years of previously successful treatment using a combination of pulse oral itraconazole and topical therapy was associated with elevated MICs to azoles *in vitro*.³⁸¹

Similar observations were made in studies of *M. pachydermatis* isolates from dogs with chronic otitis externa. One study reported that most *M. pachydermatis* isolates from canine otitis externa cases were inhibited by clotrimazole, miconazole and thiabendazole, at concentrations of 2–8 (clotrimazole), 1–4 (miconazole) or 16–32 (thiabendazole) µg/mL.³⁴¹ MICs were higher in *M. pachydermatis* isolates from chronic otitis dogs that had been previously treated with various topical ear products containing miconazole and clotrimazole.³⁵⁶ Another study examined *in vitro* antifungal susceptibility of *M. pachydermatis* isolated from cases of canine otitis clinically nonresponsive to either topical miconazole or clotrimazole and recognized MICs above the limit of detection for miconazole and clotrimazole in some isolates.³⁸² Another study reported that high MICs of itraconazole and ketoconazole in a strain of *M. pachydermatis* from canine dermatitis were associated with missense mutations in the *ERG11* gene.³⁷⁵ An additive effect of itraconazole in combination with tacrolimus³⁷⁵ likely reflected calcineurin-inhibitor binding to the immunophilin FKBP12, as shown previously for additive interactions with fluconazole in *M. furfur* and *M. sympodialis*.¹³¹

It is important to note that products formulated for treatment of canine otitis routinely contain concentrations of the drug that are at least 650 times the MIC of the wild-type target pathogen. Therefore, antifungal concentrations in topical products typically exceed, by several orders of magnitude, the highest MIC values reported to date for azole-resistant strains.

11.5.3 Biofilms

Biofilms, wherein groups of adherent microbial cells become embedded in an extracellular polymeric matrix,

may protect the microbe from the host immune system and reduce susceptibility to antimicrobial drugs.¹⁶⁰ One study evaluated the *in vitro* antifungal susceptibility of *M. pachydermatis* strains, in both their planktonic and sessile (biofilm production) forms to fluconazole, posaconazole, voriconazole, miconazole, ketoconazole, itraconazole and terbinafine; MIC values were increased by 3–6 two fold dilutions in the sessile form.³⁷⁸ Another study reported an increase in itraconazole and ketoconazole MICs by nine two-fold dilutions (<0.03 to >16 µg/mL) following biofilm formation in *M. pachydermatis*, either alone or when co-cultured with *Candida parapsilosis*.³⁸³ A further study also reported that effective concentrations (EC₅₀) of ketoconazole and itraconazole MICs increased by 18–169 and 13–124 times respectively against *M. pachydermatis* in biofilms when compared to planktonic forms.³⁸⁴ Another study reported reduced susceptibility of *M. pachydermatis* biofilms to azoles, terbinafine and amphotericin B.³⁸⁵ The significance of these important observations for therapy in clinical practice remains to be determined.

11.6 Conclusions: clinical context and implications for practice

Testing for resistance is hampered by the unsuitability of the current CLSI and EUCAST reference methods, lack of an agreed modified protocol optimized for *M. pachydermatis* and absence of clinical breakpoints for either systemic or topical therapies. Despite these critical limitations, current data suggest that the vast majority of field isolates of *M. pachydermatis* are routinely susceptible to most relevant azoles (miconazole, clotrimazole, itraconazole, posaconazole and ketoconazole). However, the evidence that reduced susceptibility of *M. pachydermatis* to commonly used antifungal drugs may develop under both field and laboratory conditions highlights the need for surveillance and vigilance for the emergence of clinically-relevant resistance. This is especially important in cases of cAD, seborrhoeic dermatitis and chronic otitis externa where repeated treatments are commonly utilized. Improved and agreed reference methods designed to overcome the specific growth requirements of *Malassezia* spp. are therefore urgently required.

12 Clinical presentations in dogs

12.1 Signalment

Malassezia dermatitis can potentially occur in dogs of any age, sex or breed, but signalment related predispositions have been reported. *Malassezia* dermatitis is often first diagnosed in dogs between one and three years of age,³⁸⁶ as might be expected in a disease that is frequently secondary to atopic dermatitis or due to genetic predisposition. Important breed predispositions are discussed in Section 7.1.^{67,240,241} There is no sex predisposition.

12.2 Historical features

Malassezia dermatitis typically presents as a pruritic dermatosis or otitis and it is a major differential diagnosis in any dog with those presenting signs. The severity of pruritus can vary, ranging from mild to very severe. In one report, the onset of clinical signs coincided with the

summer or humid months and then persisted into winter,³⁸⁷ but this apparent seasonality has not been verified to be independent of an underlying seasonal allergy. The pruritus can manifest as face rubbing, head shaking, ear scratching, paw licking/chewing, anal scooting or generalized scratching, depending on the location of infection.³⁸⁷ A pruritic facial hyperaesthesia is occasionally seen in association with *Malassezia* cheilitis.^{67,387}

12.3 Skin lesions and distribution

The skin lesions in dogs with *Malassezia* dermatitis can be localised or generalised.^{70,264,387–389} Regional dermatitis commonly occurs on the muzzle, lips, ventral neck, axillae, ventral abdomen, medial hindlimbs, interdigital skin, perineum and in the external ear canal and intertriginous areas. *Malassezia* paronychia may occur in some cases. Some clinicians have observed anecdotally that a localized area of *Malassezia* overgrowth can occur following persistent licking. On examination, skin lesions are characterised by diffuse erythema and variable amounts of kerato-sebaceous scale that can be brown (Figure 4), yellow or grey in colour.^{326,387} The skin and hair coat may become greasy and self-induced alopecia can occur due to the pruritus. When paronychia is involved, there is reddish-brown staining of the claws (Figure 5) or hair, with inflammation of the surrounding soft tissue. Chronic cases can have marked lichenification. Hyperpigmentation can also occur with chronicity, depending on the breed; for example, West Highland white terriers typically develop this change with chronic disease (Figure 6), whereas basset hounds typically do not.¹⁴⁵ Dogs with generalised lesions often have an offensive, rancid odour.

Although the occurrence of severe generalized alopecia, lichenification and hyperpigmentation in the West Highland white terrier breed has been reported previously as a form of genetic epidermal dysplasia,²⁴³ many

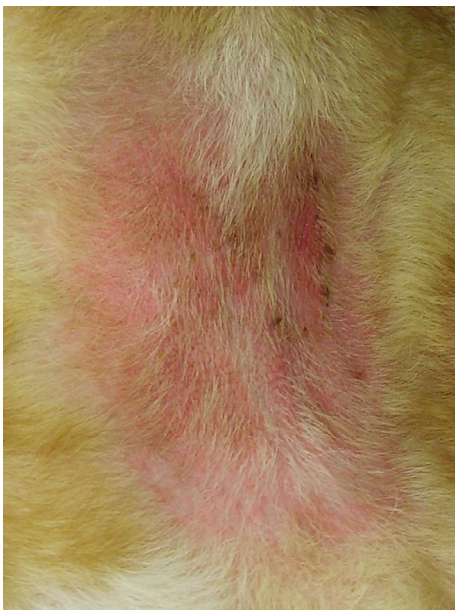

Figure 4. *Malassezia* dermatitis in the neck fold of a bull mastiff. There is a localised and demarcated area of focally intense erythema of thickened skin, with mild alopecia and kerato-sebaceous material matting the remaining hairs.

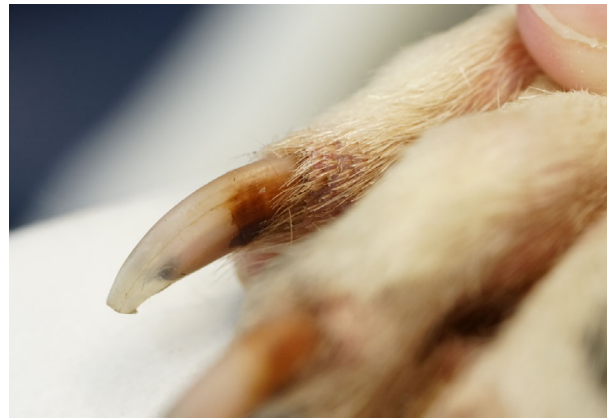

Figure 5. *Malassezia* paronychia in a dog characterised by brown discoloration of the proximal claw.

veterinary clinicians believe this condition is a severe manifestation of allergic skin disease and concurrent *Malassezia* dermatitis. Similarly, historical reports of an idiopathic seborrhoea non-responsive to etretinate in West Highland white terriers and basset hounds may have reflected untreated *Malassezia* dermatitis.³⁹⁰

Malassezia overgrowth in the ears typically results in a pruritic, erythematous, ceruminous otitis externa which results in the accumulation of a brownish discharge. As on the skin surface, the medial aspect of the pinna can become lichenified in chronic cases.

It is uncertain how the range of immunological hyperresponsiveness to *M. pachydermatis* present in dogs with *Malassezia* dermatitis (none, immediate, delayed, contact; Section 6) influences the spectrum of lesion type and severity in affected dogs.

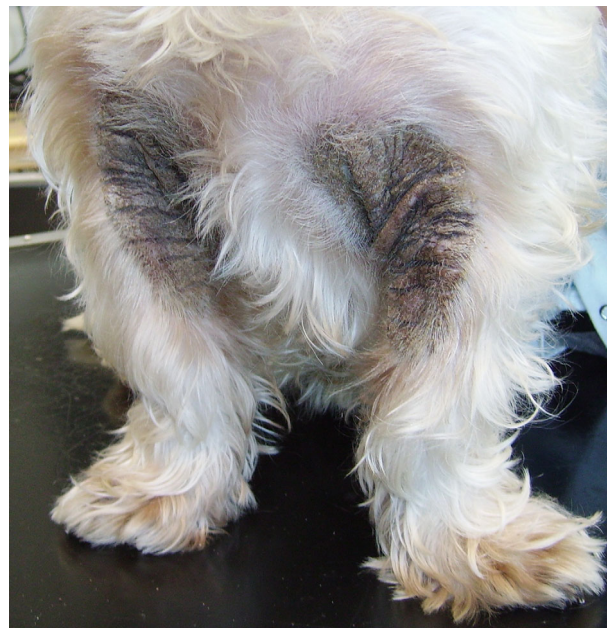

Figure 6. *Malassezia* dermatitis affecting the axillae of an atopic West Highland white terrier. The chronic lesions are characterised by symmetrical areas of intense hyperpigmentation, severe lichenification, erythema and tightly adherent crust.

12.4 Concurrent diseases

Many dogs with *Malassezia* dermatitis have concurrent dermatoses, especially hypersensitivity disorders, ectoparasitic infestation, bacterial pyoderma, endocrinopathies or cornification defects (Section 7). This can complicate the diagnosis, or lead to misdiagnoses, due to overlapping of clinical signs. These diagnostic challenges are compounded by lack of direct correlation between yeast population density and clinical signs (Section 8.5). However, it is also important to remember that in some cases, especially in predisposed breeds, there is no identifiable underlying cause and the dog's skin disease may respond completely to antifungal therapy.

12.5 Conclusions: clinical presentations in dogs

Erythema, usually with kerato-sebaceous scale, and pruritus (minimal, mild, moderate or severe) dominates the clinical presentation, often favouring intertriginous zones. There may be concurrent hyperpigmentation, lichenification, malodour, traumatic alopecia and otitis externa. Some cases present with paronychia with claw fold erythema and swelling, waxy or crusty brown exudate, red-brown claw staining, or frenzied facial pruritus with varying, sometimes subtle, cheilitis or erythema of chin/ perioral skin.

13 Clinical presentations in cats

13.1 *Malassezia* dermatitis and paronychia

The clinical presentation of feline *Malassezia* dermatitis varies markedly depending on the underlying disease (Section 7). *Malassezia* yeasts (chiefly *M. pachydermatis*) have been associated with a greasy seborrhoeic dermatitis in cats with or without concurrent paronychia.³⁹¹ Predisposing diseases include poorly defined genetic factors (in Devon Rex and sphynx cats),^{80,86,115,116} feline atopic dermatitis (which may present with concurrent bacterial pyoderma),^{85,259,284,392} adverse food reaction,^{259,284} flea bite hypersensitivity,²⁸⁴ although some recurrent cases are idiopathic despite diagnostic investigation.^{74,284} There is conflicting evidence for diabetes mellitus as a predisposing cause.^{82,284,393} Feline immunodeficiency virus-positive cats have been shown to carry more *Malassezia* organisms compared with normal cats but this was not associated with any clinical signs.³⁹⁴

Affected Devon Rex and sphynx cats typically show mild to marked greasy seborrhoea with alopecia (in Devon Rex) and hyperpigmentation or reddish-brown surface discolouration and variable erythema affecting the axillae, groin, ventral neck and predominantly ventral interdigital regions. This is commonly accompanied by a greasy, tightly adherent brown exudate on the claws and/or in the claw folds of multiple digits. Pruritus is not typically a feature.^{78,115}

Less common presentations reported in Devon Rex cats include generalized seborrhoea sicca, a greasy seborrhoea affecting the ventral neck and head and pruritus.¹¹⁵ In sphynx cats in particular, there may be some elevated *Malassezia* carriage (compared with normal cats) which may result in greasiness without overt inflammation or seborrhoea.^{85,116}

Allergic cats show more variability in their presentation and may present with concurrent bacterial

pyoderma.^{85,392} Dermatitis may be localised or generalised with pruritus, alopecia, erythema and greasy exudate. The most commonly affected body regions include the face, chin, neck, limbs, abdomen and ear canals (see below). Less commonly affected regions include the tail and the pinnae, and in contrast with Devon Rex and sphynx cats, the interdigital regions and claw folds.^{85,259,284}

Although uncommon, *Malassezia* overgrowth should be considered in every case of localised or generalised erythema associated with seborrhoea in cats.²⁸⁴

13.2 Feline idiopathic facial dermatitis

Feline idiopathic facial dermatitis is an uncommon skin disorder of presumed hereditary origin.³⁹⁵ Persian, and anecdotally Himalayan, cats are predisposed.^{395–397} Affected cats show progressive skin lesions on the face characterised by symmetrical erythema and exudate with black waxy material matting the distal hair particularly in facial folds, perioral, periocular and preauricular regions. Secondary excoriations may be present in severe cases. A concurrent bilateral erythematous otitis with black waxy exudate was reported in seven of 13 cats.³⁹⁵

Malassezia overgrowth has been found with cytology methods in approximately half of the reported cases, and more often with concurrent coccoid and/or rod bacterial overgrowth.^{395–397} In one study five of 12 cats partly responded to antimicrobial agents. Of these cats, four received ketoconazole 10 mg/kg for 14–42 days either alone (2/4 cases) or with concurrent antibiotics (two of four cases). A partial reduction in pruritus and exudate was noted in three of four cats. A 2% chlorhexidine 2% miconazole shampoo three times weekly in one case was used to a good initial response but was subsequently withdrawn due to irritation. It was concluded based on the partial responses seen in some cats that concurrent infection may be a complicating factor in this disease.³⁹⁵

13.3 Feline paraneoplastic alopecia

Feline paraneoplastic alopecia is a clinically distinct disease that occurs secondary to carcinoma of the liver, bile duct, intestine and pancreas, as well as with a neuroendocrine pancreatic carcinoma and hepatosplenic plasma cell tumour.^{82,83,398–405} The typical clinical presentation is of ventral alopecia with inelastic, thin, smooth and shiny but not fragile skin; adjacent hairs can be easily epilated. Limbs, paws and ears may be variably affected and dry crusting and fissuring of the footpads is occasionally noted. It is a non-pruritic disease unless there is significant secondary *Malassezia* (or bacterial) infection, usually manifest by crusts and brown exudate.^{399–405} Systemic azoles (itraconazole 5–10 mg/kg once daily²⁸⁴ and ketoconazole 5 mg/kg twice daily⁴⁰¹) have been used in a limited number of cases to successfully treat concurrent *Malassezia* infections, resulting in reduced pruritus, better quality of life and reduction of inflammatory changes on histopathology, albeit without improving the poor prognosis associated with frequently metastatic neoplasia.^{83,401}

13.4 Thymoma-associated exfoliative dermatitis

Significant colonisation of the skin with *Malassezia* organisms may be associated with some cases of thymoma-associated exfoliative dermatitis. This is a paraneoplastic

syndrome characterised by a generalised marked inflammatory exfoliation with patchy hair loss and easily epilated hair, and variably thickened skin which may be fissured or ulcerated. While this disease has been reported a number of times, only two reports confirmed associated *Malassezia* overgrowth.^{251,406} The remaining reports could not definitively confirm the presence of a thymoma,⁸³ or failed to demonstrate yeast on histopathology, though skin cytology and/or culture was not noted to be performed in all cases.^{407–410}

A single cat with thymoma and confirmed *Malassezia* overgrowth (confluent growth on contact plates) that was treated surgically and followed up showed no yeast growth on contact plate culture six months following surgical removal. The only additional treatment for the *M. pachydermatis* initially isolated in this time was two baths in a selenium sulphide shampoo, indicating a likely strong association between yeast overgrowth and the thymoma.²⁵¹

13.5 Superficial necrolytic dermatitis

Superficial necrolytic dermatitis (syn. necrolytic migratory erythema, metabolic epidermal necrosis) has been very rarely reported in cats, in association with pancreatic carcinoma, thymic amyloidosis, hepatopathies and intestinal lymphoma.^{83,411–414} Clinical signs include scaling and variable alopecia of the trunk and limbs, with or without pruritus, and ulceration and crusting of the oral mucocutaneous junctions and interdigital regions. Two authors have reported secondary *Malassezia* dermatitis in conjunction with this presentation.^{83,415}

13.6 Feline acne

Malassezia organisms have been identified with cytology methods and/or histopathology in 16% (four of 25) to 18% (four of 22) of reported cases of feline acne.^{252,416} *Malassezia* organisms in feline chin acne have been identified not only on the skin surface, but also occasionally within comedones.⁴¹⁷ There is some debate over the role of the pathogenicity of *Malassezia* spp. in chin acne,⁴¹⁶ although two cases were reported in conference proceedings which responded poorly to antibiotics, had yeast organisms on both histopathology and cytology samples, and showed a good clinical and mycological response to a 30 day course of oral ketoconazole.⁷⁴

13.7 Otitis externa

Malassezia pachydermatis is the predominant *Malassezia* yeast isolated from cats' ears; frequency of isolation is increased in cats with otitis externa.⁴¹⁸ In addition, *M. furfur* has been isolated from the ear of a healthy cat, whereas *M. sympodialis*^{56,76,419} and *M. nana*^{24,116} have been recovered from both healthy cats and cats with otitis externa. Whilst many healthy cats have ear canals apparently devoid of *Malassezia* yeasts, despite attempts to associate particular yeast counts with ear disease,⁴²⁰ there is a subset of cats which can carry large numbers of yeast in their ear canals without evidence of otitis externa.^{114,393,421} It has been suggested that the finding of excessive otic *Malassezia* organisms in the absence of clinical signs may potentially be indicative of occult systemic disease.¹¹⁴

Some feline cases of otitis externa are associated with *Malassezia* yeasts as the sole pathogen,^{256,419,421,422} whereas concurrent bacteria^{421,422} and/or *Otodectes cynotis* mites^{393,422} are commonly identified. Affected cats usually present with excessive dark to black waxy to flaky exudate, erythema, with variable otalgia, canal wall hyperplasia, pruritus and odour.^{79,393,419} Underlying diseases or co-morbidities include otocariasis,^{256,393} atopic dermatitis,^{85,284,392} and feline idiopathic facial dermatitis,³⁹⁵ although some cats have no identified predisposing diseases.^{256,419}

Interestingly, unlike the situation in seborrhoeic basket hounds,^{98,145} there is no evidence for an increased prevalence of *Malassezia* otitis in seborrhoeic Devon Rex and sphynx cats prone to *Malassezia* dermatitis.^{80,115}

13.8 Conclusions: clinical presentation in cats

Erythema, usually with kerato-sebaceous scale, and pruritus (minimal, mild, moderate or severe) dominates the clinical presentation. There may be concurrent otitis externa and an observed breed predilection (Devon rex, sphynx). *Malassezia* dermatitis might feature in cats that present with a phenotype of allergic skin disease, idiopathic facial dermatitis (Persian/ Himalayan), feline acne and serious internal medical disorders such as feline paraneoplastic alopecia and thymoma-associated exfoliative dermatitis.

14 Summary of the diagnostic approach

14.1 Dog or cat presents with inflammatory skin disease potentially associated with *Malassezia* yeasts

Clinical features are summarised in Sections 12.5 and 13.8.

14.2 Establish whether *Malassezia* yeasts can be identified cytologically (or by quantitative culture using contact plates or detergent scrub; not routine swab culture) in lesional areas. Counts may be high but not necessarily so

Yes: Initiate trial therapy with appropriate topical and or systemic antifungal product.

No: Sample more sites; use an alternative sampling method; reconsider diagnosis.

Additional diagnostic evaluations and treatments may be indicated at first presentation depending on the clinical signs, including cases where signs suggest, for example, paraneoplastic disorders in cats.

14.3 Evaluate the clinical and mycological response to appropriate topical (three to four weeks) and or systemic (two to four weeks) antifungal therapy

- 1 Complete clinical & mycological response - diagnose *Malassezia* dermatitis; consider an underlying cause.
- 2 Partial clinical, complete mycological - diagnose *Malassezia* dermatitis; investigate/treat ongoing underlying skin disease.

- 3 No clinical response, complete mycological - consider yeast presence incidental to other inflammatory disease.
- 4 Partial clinical & mycological response - suspect *Malassezia* dermatitis; review compliance; extend or intensify antifungal therapy.
- 5 Neither clinical or mycological response - review compliance; consider abnormal drug absorption or metabolism, or drug resistance; change antifungal treatment and re-assess.

15 Therapy

15.1 General considerations

Treatment of *Malassezia* dermatitis typically involves the use of topical and/or systemic antifungal medications.³⁸⁸ Topical treatments such as shampoos, gels and lotions are appropriate for *Malassezia* dermatitis since the yeast is located within the stratum corneum. Shampoos are particularly interesting because they have a mechanical action that may reduce scaling and greasy exudation; some are formulated with keratoregulating agents such as phytosphingosine, ammonium lactate, zinc gluconate and salicylic acid.⁴²³ Although some clinicians favour other topical formulations and combinations (such as mousse, wipes, sprays, particularly in skin folds), these products currently require further evaluation to justify their therapeutic recommendation. Systemic therapies are often more expensive than topical therapies but may be necessary in cases where topical therapy is challenging for the owner/patient affiliation or otherwise ineffective. However, a combined topical/systemic approach may be optimal in some dogs with generalized and/or severe lesions: one study (published in abstract form) showed that a combination of oral ketoconazole and 2% miconazole /2% chlorhexidine shampoo was more effective and allowed a better speed of cure than either topical or systemic treatment used alone.⁴²⁴ It is also important to diagnose and treat the underlying cause responsible for the proliferation of the yeast (Section 7).

15.2 Development of the consensus on therapy

Many *in vitro* studies have been published showing the potential activity of various molecules against yeast and notably *Malassezia* spp. (reviewed in Section 10). Unfortunately trials assessing the *in vivo* efficacy of antifungal treatment for *Malassezia* dermatitis in dogs are few in number and commonly involve only small group sizes with resultant low statistical power. This is quite surprising if we consider that *Malassezia* dermatitis is a very common condition in veterinary medicine. In cats data are even less numerous and only open studies have been reported.

The authors approached the development of consensus guidelines on therapy on two levels. Firstly, we performed a systematic search and review of relevant published trial data with grading of the study quality to provide evidence based conclusions on the strength of recommendation, updating a previous review.⁴²⁵ Secondly, we provided summary practice guidelines that are primarily evidence-based and drawn from part one and

included a component of expert opinion where the evidence based data is limited or absent. Consequently, the concluding summary is a combination of evidence base and consensus of opinion.²

For the systematic review we utilised the Strength of Recommendation Taxonomy (SORT), a comprehensive taxonomy for evaluating the strength of recommendation based on a body of evidence and the quality of individual studies (Table 2).² This schedule emphasises the use of patient-oriented outcomes and is designed to simplify the interpretation of studies and facilitate their incorporation into evidence-based patient care. Studies for review were identified by electronic searches of the PubMed (National Center for Biotechnology Information, US National Library of Medicine 8600 Rockville Pike, Bethesda MD 20894, USA) and CAB Direct (Centre for Agriculture and Bioscience International, Wallingford, UK) databases (keywords were *Malassezia*, treatment, dog, cat) and manual searches of *Advances in Veterinary Dermatology*, Volumes 1–8 (no relevant studies identified). The studies were included if presented in full or abstract form in a peer-reviewed journal; studies presented only in conference proceedings were not evaluated due to likely infrequent availability to the wider veterinary dermatology community.

15.3 Review of trial data in dogs: systemic treatments

15.3.1 Azole derivatives

Ketoconazole: In spite of the widespread practice use of ketoconazole to treat *Malassezia* dermatitis, only a few studies evaluated the efficacy of this azole *in vivo*. Studies were either randomized and controlled,^{146,379,424,427} or controlled without blinding⁴²⁸ (Table 3) involving relatively small group sizes (7–12 dogs). Together, these studies indicated that the use of ketoconazole at an oral dosage of 5–10 mg/kg/day is most often either completely or partially effective, when given fasted, to

Table 2. (a) The Strength of Recommendation Taxonomy (SORT) (b) descriptors for Levels of Evidence (LoE) for individual studies

(a)	
Strength of Recommendation	Definition ²
A - Strong	Based on consistent and good quality patient-oriented evidence
B - Moderate	Based on inconsistent or limited quality patient-oriented evidence
C - Weak	Recommendation based on consensus, usual practice, disease-oriented evidence or case series
(b)	
Level of Evidence	Definition for treatment studies ²
1 - Good quality patient-oriented	High quality individual RCT, or meta-analysis of consistent RCTs
2 - Limited quality patient-oriented	Lower quality clinical trial, cohort study, case-control study
3 - Other evidence	Recommendation based on consensus, usual practice, disease-oriented evidence or case series

RCT randomized controlled trial.

Table 3. Clinical trials of oral ketoconazole in the treatment of canine *Malassezia* dermatitis in dogs and level of evidence (LoE)

Study	Design	Dose used	Clinical outcome	Adverse effects	Comment	LoE
Bensignor 2001 ⁴²⁸	RCT-UB (10 dogs per group)	5 OR 10 mg/kg once daily	7/20 complete response, rest partial	In 10 mg/kg group: vomiting [n = 2], anorexia [n = 1], apathy [n = 1]	Small group sizes; two KTZ doses compared	2
Rosales <i>et al.</i> 2005 ¹⁴⁶	RCT-B (seven dogs received KTZ)	5-10 mg/kg twice daily	4/7 > 50 % clinical improvement	Nil	Small group sizes and concurrent cefalexin therapy limits interpretation. Compared with terbinafine.	2
Bensignor 2006 ⁴²⁷	RCT-B (10 dogs received KTZ)	10 mg/kg once daily	4/10 complete response, 6/10 partial	Nil	Small group sizes; compared to pulse ITZ	2
Bensignor <i>et al.</i> 2012 ⁴²⁴	RCT-B (10 dogs)	10 mg/kg once daily	83% improvement at six weeks	Not specified	Abstract publication only; compared to shampoo alone or combined with KTZ	2
Sickafoose <i>et al.</i> 2010 ³⁷⁹	RCT-B (12 dogs received KTZ + cefalexin)	5-10 mg/kg once daily	7/12 > 50 % clinical improvement	6/12 dogs: transient anorexia [n = 2], vomiting [n = 3], vomiting and soft stool [n = 1]	Concurrent cefalexin therapy limits interpretation. Compared with FCZ.	2

FCZ fluconazole, ITZ itraconazole, KTZ ketoconazole, RCT-B randomised controlled trial – blinded, RCT-UB randomised controlled trial – unblinded.

Table 4. Clinical trials of oral itraconazole in the treatment of canine *Malassezia* dermatitis and level of evidence (LoE)

Study	Design	Dose used	Clinical outcome	Adverse effects	Comment	LoE
Pinchbeck <i>et al.</i> 2002 ⁴³⁰	RCT-B (10 dogs per group)	5 mg/kg once daily or two consecutive days/week, for 21 days	Median lesion score reduced by 60% (pulse) and 31% (daily)	Nil	Small group sizes; two ITZ intervals compared	2
Kumar <i>et al.</i> 2002 ⁴⁸¹	RCT-BNS (11 dogs received ITZ)	5 mg/kg once daily	All responded fully by d22	Nil	Combined with twice weekly selenium sulphide shampoo. No statistical analyses	3
Bensignor 2006 ⁴²⁷	RCT-B (10 dogs received ITZ)	5 mg/kg once daily for two consecutive days/week	5/10 complete response, 5/10 partial	Transient vomiting [n = 2], inappetence [n = 1]	Small group sizes; compared with KTZ	2

ITZ itraconazole, KTZ ketoconazole, RCT-B randomised controlled trial – blinded, RCT-BNS randomised controlled trial – blinding not specified.

improve both clinical signs and cytological or colony counts from dogs suffering from *Malassezia* dermatitis (Strength of Recommendation (SoR) B-moderate). The length of treatment varied between three and four weeks in most cases. Whilst one un-blinded randomised study of 20 dogs suggested that there was no significant difference in efficacy between 5 and 10 mg/kg/day of ketoconazole administered once daily for three weeks,⁴²⁸ there is insufficient evidence to comment specifically on the efficacy of the various doses used (5 or 10 mg/kg, once or twice daily). Reports of improved efficacy with KTZ at doses of 10 mg/kg twice daily³⁸⁶ do not appear to have been subjected to critical comparative trials. Adverse reactions are regularly reported with the use of ketoconazole in dogs; a retrospective study of 632 dogs that received a median daily dose of 10 mg/kg reported adverse effects in 14.6%, including primarily vomiting

(7.1%), anorexia (4.9%), lethargy (1.9%) and diarrhoea (1.1%).⁴²⁹ Adverse effects were significantly more frequent in dogs receiving concurrent ivermectin or ciclosporin.⁴²⁹

Itraconazole: Itraconazole appears to be effective based on the few clinical trials that have evaluated its efficacy for the treatment of canine *Malassezia* dermatitis^{427,430} (Table 4; SoR B-moderate). Two were comparative versus ketoconazole. Therapeutic doses recommended are variable with 5 mg/kg once daily, or for two consecutive days a week, being most often used. In two relatively small studies there were no significant differences in any results between itraconazole pulse therapy (two days on, five days off) and the daily administration of either itraconazole or ketoconazole.^{427,430} The pulse therapy approach reflects predicted accumulation of this lipophilic drug in the stratum

Table 5. Clinical trials of oral fluconazole and terbinafine in the treatment of canine *Malassezia* dermatitis with level of evidence (LoE)

Study	Drug	Design	Dose used	Outcome	Adverse effects	Comment	LoE
Sickafoose <i>et al.</i> 2010 ³⁷⁹	Fluconazole	RCT-B (13 dogs received FCZ + cefalexin)	5–10 mg/kg once daily	8/13 > 50 % clinical improvement	6/13 dogs: transient vomiting [n = 4], vomiting and soft stool [n = 1], diarrhoea [n = 1]	Concurrent cefalexin limits interpretation. Compared with KTZ + cefalexin.	2
Rosales <i>et al.</i> 2005 ¹⁴⁶	Terbinafine	RCT-B (8 dogs received terbinafine + cefalexin)	30 mg/kg once daily	3/8 > 50 % clinical improvement	Nil	Small group sizes and concurrent cefalexin limits interpretation. Compared with KTZ + cefalexin.	2
Berger <i>et al.</i> 2012 ⁴³²	Terbinafine	RCT-B (10 dogs received terbinafine at either dose)	30 mg/kg once daily OR on two consecutive days/week, for 21 days	8/10 > 50% clinical improvement in both groups	Mild signs in 3/10 dogs in both groups (overall 6/20); vomiting [n = 2], diarrhoea [n = 2], anorexia [n = 1], panting [n = 1]. Elevated ALT in 1 dog.	Small group sizes. Complete clinical resolution in only 3/20 dogs at d21. Eight dogs developed pyoderma.	2

ALT alanine aminotransferase, KTZ ketoconazole, RCT-B randomised controlled trial – blinded.

Table 6. Clinical trials of 2% miconazole/ 2% chlorhexidine and 3% chlorhexidine shampoos in the treatment of canine *Malassezia* dermatitis with level of evidence (LoE)

Study	Product	Design	Frequency	Clinical outcome	Adverse effects	Comment	LoE
Bond <i>et al.</i> 1995 ¹⁴⁵	2% miconazole/ 2% chlorhexidine	RCT-B (16 basset hounds received MC-CH)	Every third day	15/16 "marked improvement"	Nil	Compared to 0.25% selenium sulphide shampoo	1
Maynard <i>et al.</i> 2011 ²⁶⁸	2% miconazole/ 2% chlorhexidine	RCT-B (32 dogs received MC-CH)	Twice weekly	Good (≥50%) response in 91% of dogs	Nil	Compared to CH	1
Bensignor <i>et al.</i> 2012 ⁴²⁴	2% miconazole/ 2% chlorhexidine	RCT-B (10 dogs)	Twice weekly	85% improvement at 6 weeks	NR	Abstract publication only	2
Maynard <i>et al.</i> 2011 ²⁶⁸	3% chlorhexidine	RCT-B (22 dogs received CH)	Thrice weekly for 2 weeks, then twice weekly for two weeks, then weekly if needed	Good (≥50%) response in 86% of dogs	Transient self-limiting pododermatitis [n = 1], increased pruritus [n = 2], exfoliation [n = 2]	Compared to MC-CH	1

CH 3% chlorhexidine, MC-CH 2% miconazole/2% chlorhexidine, RCT-B randomised controlled trial – blinded.

corneum⁴³¹ and reduces costs and likely also side-effects of this relatively well-tolerated azole. Adverse effects seem to be less frequent with itraconazole compared to ketoconazole: transient vomiting and decreased appetite were relatively rare in the published studies (four of 49 cases).

Fluconazole: Only one study evaluated the use of fluconazole for the treatment of *Malassezia* dermatitis in dogs.³⁷⁹ This double-blind randomized controlled study comprising 25 dogs showed that fluconazole at 5–10 mg/kg orally once daily administered with food was as effective as ketoconazole at 5–10 mg/kg orally once daily for controlling the clinical and cytological signs of *Malassezia* dermatitis (Table 5). Concurrent use of cefalexin in both treatment

groups limits full clinical interpretation (LoE 2; SoR B-moderate). Transient side effects of vomiting [n = 5] and or diarrhoea [n = 2] were seen in six of 13 dogs.

15.3.2 Allylamine derivatives

Terbinafine: One study showed that oral terbinafine at 30 mg/kg orally once daily for 21 days reduced yeast counts (assessed by contact plates) in a group of seven basset hounds with high skin population densities of *M. pachydermatis* but without dermatitis; mycological efficacy was numerically but not statistically inferior to oral ketoconazole at 10 mg/kg once daily.²⁸¹ This low-powered study was not included in the SORT analysis because the outcome is disease-orientated (yeast

count) rather than patient-oriented (no clinical scoring) (Level of evidence (LoE) 3).² The efficacy of terbinafine was subsequently assessed in two clinical trials, either randomized and controlled by a different interval of dosing of terbinafine, or in a small study with concurrent cefalexin therapy (Table 5; SoR C-weak).^{146,432} Monitoring of serum hepatic enzymes has been recommended for dogs receiving daily oral terbinafine in view of reports of reversible, mild-moderate elevations of alanine aminotransferase and serum alkaline phosphate.^{432,433} A study designed to integrate pharmacokinetic data with previous MIC data in 10 healthy dogs treated with 30 mg/kg orally once daily for 21 days indicated that terbinafine does not achieve high stratum corneum and sebum concentrations compared with serum values; achieved concentrations barely exceeded previously reported *in vitro* MIC values.³⁵⁰ These and other pharmacokinetic data might indicate preferential utility for systemic mycoses,⁴³⁴ or the need for further dose optimisation for superficial mycoses in dogs.

15.4 Review of trial data in dogs: topical treatments

15.4.1 Miconazole and chlorhexidine

Miconazole is an azole derivative present in various shampoos, creams or lotions. A combination of 2% miconazole and 2% chlorhexidine in a shampoo formulation is licensed for the treatment of canine *Malassezia dermatitis* in a number of countries, primarily in Europe and Australia. Consistent high efficacy has been reported in randomised controlled trials (RCT) (Table 6; SoR A-strong). In one RCT study, clinical efficacy was associated with marked reductions in skin population densities of both *M. pachydermatis* and total bacteria/ staphylococci, assessed using a detergent scrub technique.¹⁴⁵ In the second RCT, yeast counts were assessed by tape-strips whereas bacterial populations were not assessed.²⁶⁸ Adverse effects to miconazole/ chlorhexidine were not reported amongst the 48 dogs treated in these two studies,^{145,268} although the UK data sheet of the product used mentions 'very rare' or 'exceptional' pruritic or erythematous reactions (<http://www.noahcompendium.co.uk/?xml:id=-449936>).

15.4.2 Other chlorhexidine products

In a RCT, a 3% chlorhexidine shampoo was reported to be more than 50% effective in 18 of 22 treated dogs²⁶⁸ (Table 6; LoE 1; SoR B-moderate) and was judged not inferior to 2% miconazole and 2% chlorhexidine. Four dogs had transient and self-limiting side effects; the UK data sheet reports that self-limiting pruritus and erythematous reactions are 'common' and that conjunctival inflammation may occur. A 3% chlorhexidine and 0.5% climbazole shampoo was compared with a 2% miconazole and 2% chlorhexidine shampoo in a blinded design in 16 basset hounds (seven healthy, nine greasy) by a single application of each product to one side of the body.⁴³⁵ Both yeast counts (by contact plates) and clinical scores reduced during the fourth day trial period but clinical interpretation was limited by the varied clinical status of the subject dogs in this published abstract (LoE 3).

15.4.3 Miconazole

A small RCT of 1% and 2% miconazole conditioners of low statistical power showed reductions in clinical scores and yeast counts but no statistical difference when compared with vehicle control (LoE 2).⁴³⁶

15.4.4 Climbazole

A 2% climbazole shampoo had rapid mycological efficacy in a small disease-oriented (contact plate yeast count) rather than patient-oriented (no clinical scoring) RCT involving six treated and five control beagle dogs without skin lesions (SoR not applicable).²⁸² Similarly, a short, open study of wipes containing 0.5% climbazole, 0.3% chlorhexidine and Tris-EDTA assessed only yeast counts but not clinical parameters.²⁸³

15.4.5 Enilconazole

A 0.2% enilconazole lotion is licensed in some countries for the topical therapy of dermatophytosis in dogs, cattle and horses. Only one retrospective study of 12 cases of generalised *Malassezia dermatitis* reported treatment with a 0.2% enilconazole lotion (frequency of application not detailed) in association with oral ketoconazole.⁴³⁷ Although a complete mycological recovery was described, no specific report of clinical improvement was available (LoE 3; SoR not applicable).

15.4.6 Others

In a RCT involving 35 dogs, 20 received a commercially-available mixture of essential oils (Malacalm, Flora Srl Oli essenziali, Lorenzana, Italy) twice daily for one month, 10 received oral ketoconazole 10 mg/kg orally once daily and 2% chlorhexidine twice weekly and five dogs served as untreated controls.⁴³⁸ Whilst the authors reported a >50% improvement in clinical scores in nine of 10 of dogs treated with essential oils, and in all of the dogs treated with ketoconazole and chlorhexidine, interpretation is limited by unclear randomisation and blinding procedures, and failure to report pre- and post-treatment group clinical scores (mean or median, range) in the three treatment groups (LoE 2; SoR C-weak). An unusual feature of this study was reported lack of relapse 150 days post-treatment in all of the essential oil-treated dogs. Further evaluation of this product is warranted.

Selenium sulphide, piroctone olamine, benzalkonium chloride, triclosan formulated either in gels, shampoos, lotions, sprays or spot-on are also available but there is insufficient evidence to recommend their use at this time. In an open case series published in abstract form, a shampoo combination of piroctone olamine and ammonium lactate and a lotion (piroctone olamine and salicylic acid) reduced clinical scores and cytological yeast counts in 14 seborrhoeic dogs with high *Malassezia* counts (LoE 3),⁴³⁹ these data should be confirmed in a RCT.

15.5 Review of trial data in cats

In cats only open case series have been described, using oral itraconazole at varying doses and intervals (Table S7, LoE 3, SoR C-weak).^{85,86,284} As for dogs, topical antifungal agents such as miconazole, chlorhexidine or climbazole are likely to be beneficial but there is no data to substantiate this, other than anecdotal reports.

15.6 Antifungal drug formulation

The relatively high cost of certain innovator-formulated drugs such as itraconazole has stimulated the compounding of bulk powder formulations by pharmacists in an attempt to reduce costs to clients. This is legal in some (but not all) countries under certain conditions. In a randomised cross-over study involving nine healthy beagle dogs, neither generic nor compounded itraconazole was bioequivalent to the innovator-formulated product.⁴⁴⁰ Pharmacokinetic analyses showed that the compounded formulation had very low absorption and bioavailability (5% of innovator product), yielding likely ineffective plasma concentrations, whereas the generic and reference products were broadly similar to each other. In a similar study of eight healthy cats, itraconazole compounded in both capsules and suspension was absorbed poorly and inconsistently.⁴⁴¹ In a field study of 95 dogs and 20 cats receiving either compounded, generic or innovator-formulated itraconazole for systemic mycoses, sub-therapeutic concentrations were detected in 95.2% of animals receiving the compounded formulation but in only 12.5% or less of the animals treated with generic or reference formulations.⁴⁴² The poor bioavailability of itraconazole in compounded formulations and in some cases treatment failures, has been attributed to the absence of cyclodextrin, a carrier compound shown to improve gastro-intestinal absorption.^{443,444} A study of compounded fluconazole suspensions showed poor pharmaceutical accuracy (median 74% of target concentration).⁴⁴⁵ These data indicate that use of compounded azole formulations must not be used; innovator-formulated or proven generic formulations are preferred.

There appears to be no published data on the comparative efficacy of different topical formulations containing the same or similar ingredients. This may be especially relevant with over-the-counter formulations where regulatory assessment of product quality may be less exacting and with molecules such as chlorhexidine whose stability may vary under different conditions.⁴⁴⁶ Both published RCT of a 2% miconazole and 2% chlorhexidine shampoo with strong evidence of efficacy utilised the same innovator-formulated licensed product (Malaseb, Derm-care Vet, Slacks Creek, Queensland, Australia),^{145,268} one of these studies also showed good activity from a licensed 3% chlorhexidine shampoo (Microbex®, VIRBAC SA, Carros, France).²⁶⁸

15.7 Conclusions: consensus guidelines for treatment of *Malassezia* dermatitis in dogs and cats

Amongst the various treatments utilised for *Malassezia* dermatitis in dogs, strong evidence (SoR A) is available only for the use of a 2% miconazole and 2% chlorhexidine shampoo, used twice weekly (two RCT with LoE 1). This may be considered to be the topical treatment of first choice, where available and locally approved, and when owners are able to apply the product effectively. Moderate evidence (SoR B) is available for a 3% chlorhexidine shampoo (a single study of LoE 1).

For canine *Malassezia* dermatitis, there is moderate evidence (SoR B) for the use of ketoconazole at 5–10 mg/kg orally once or twice daily (five studies of LoE ≥ 2); and itraconazole at 5 mg/kg orally once daily or two

consecutive days per week (two studies of LoE ≥ 2). Based on current limited evidence, the use of either of these two azoles is justified in canine cases and the final choice may depend on regional differences in availability, regulatory status and cost. Rationale for itraconazole instead of ketoconazole includes the potential for intermittent dosing and a perceived tendency for itraconazole to be better-tolerated. However, definitive statistical evidence of superior safety and/or efficacy is lacking and cost-benefit analysis makes ketoconazole a more practical choice in some countries. Compounded formulations must be avoided due to unreliable bioavailability. Evidence for fluconazole is limited to a single study (LoE 2) where it was used at 5–10 mg/kg orally once daily in conjunction with cefalexin. Thus fluconazole requires further assessment, especially since *in vitro* MIC values are routinely the highest amongst antifungal azoles utilised in veterinary medicine (See Section 10); this may correlate with intermittent anecdotal reports of treatment failures. Terbinafine warrants further evaluation due to partial beneficial effects in two trials (SoR C-weak) and questionable stratum corneum concentrations in a pharmacokinetic study when given at the current dose of 30 mg/kg orally once daily.

In cats, there is weak evidence only (SoR C) for the use of itraconazole at doses of 5–10 mg/kg orally once daily; or 5 mg/kg on a seven days on/ seven days off protocol. In view of this limited data, good safety profile and in line with guidelines for feline dermatophytosis,¹ itraconazole should be considered as the systemic azole of first choice in this species for *Malassezia* dermatitis. Topical chlorhexidine and azole products have not been evaluated although their use is intuitive as adjunctive or sole treatments where application is practicable and clinically appropriate, such as in localised infections.

16 Prevention of *Malassezia*-associated skin diseases in dogs and cats

16.1 Management of underlying diseases

As *Malassezia* yeasts are part of the normal cutaneous microflora, complete elimination of the organism is unrealistic even with effective treatment.⁴⁴⁷ Relapsing infections are common where there is persistence of the underlying cause for the yeast overgrowth. The standard clinical approach is identification and treatment of underlying causes, whenever possible,^{388,391,447–449} though there is surprisingly limited reported evidence to document its efficacy (Table S8).

16.2 Topical therapy

When predisposing factors cannot be identified or controlled in an animal suffering from recurrent *Malassezia* infections, regular topical or pulsed oral antifungal therapy have been recommended to minimise the frequency of infection relapses that cannot be managed by other means.^{391,447,450}

Multiple topical therapies have been shown to be effective for treatment of *Malassezia* dermatitis in dogs and cats (See Section 15). In addition, because of a lower risk for toxicity, topical treatments have also been recommended (if practical and not causing irritation^{426,450}) as

preferable to systemic treatments for long-term therapy in chronically relapsing cases.⁴⁴⁸ Furthermore, there is evidence that bathing dogs in 2% chlorhexidine/2% miconazole shampoo every three days can reduce oral carriage of *Malassezia* organisms.⁹⁹ However, recommendations for weekly antifungal shampoo bathing as a preventive strategy to reduce the frequency of recurrent *Malassezia* dermatitis appear anecdotal rather than evidence-based.⁴⁴⁷ Studies *in vitro* that demonstrate shampoo persistence on hairs may or may not be relevant to persistence on skin,⁴⁴⁸ and studies *in vivo* on topical therapy persistence were conducted in normal dogs rather than in dogs with *Malassezia* dermatitis.^{282,283}

In a comparative study of a commercial mixture of essential oils (Malacalm; Flora s.r.l., Lorenzana, Pisa, Italy) applied twice daily for one month to 20 dogs with recurrent *Malassezia* dermatitis, and combined ketoconazole (10 mg/kg orally once daily) and 2% chlorhexidine shampoo (twice weekly) for 21 days in 10 dogs, both groups showed good clinical and cytological improvements at day 30.⁴³⁸ When reviewed at day 180, all conventionally treated dogs had reportedly relapsed whereas dogs treated with the essential oil formulation had not.⁴³⁸ Interpretation of this study is limited by incomplete randomisation, clinical and cytological data in the publication and an absence of within and between-group statistical comparisons at day 180-time point; consequently this treatment cannot be recommended for prevention without further critical assessment.

With respect to prevention of recurrent *Malassezia* otitis, while studies *in vitro* have demonstrated antimicrobial efficacy of ear cleaners,^{451,452} there are only two studies examining topical therapy for prevention of *Malassezia* otitis. A single study examining dogs with recurrent allergic otitis showed a favourable outcome to a once weekly ear cleaner containing chloroxylonol and cerumenolytics (Epiotic, Virbac Carros, France) and concurrent twice weekly three drops per ear of 0.0584% topical hydrocortisone aceponate solution (Cortavance, VIRBAC SA, Carros, France) (95% chance of remaining free of relapse at day 180) compared with weekly ear cleaner alone (50% chance of remaining infection free at day 180).⁴⁵³ However, the lack of detail regarding the nature of the infection for both pre-treatment and relapsing otitis, makes a recommendation specifically for the prevention of *Malassezia* otitis difficult. A second open study examining twice weekly 2% acetic acid 2% boric acid topically showed the protocol unsuccessful in preventing relapse of *Malassezia* otitis beyond previously documented relapse intervals in six of eight cases.⁴⁵⁴

16.3 Pulsed oral antifungal therapy

Oral antifungal drugs might be given by an intermittent/pulsed dosing schedule to try to prevent recurrent *Malassezia* dermatitis (and otitis) in dogs and cats, particularly where topical therapy is either ineffective or impractical. Overall, published evidence that substantiates the efficacy of this approach is lacking. Whilst the clinical risk appears low, it should be noted that intermittent use of oral antifungal drugs could potentially predispose to development of antifungal resistance (See Section 11).^{351,381} A dosing regimen of two consecutive days

per week ("weekend therapy") has been investigated or proposed for three oral antifungal drugs. Terbinafine (30 mg/kg orally once daily, two days on/ five days off) reduced yeast counts in tape-strips from dogs with *Malassezia* dermatitis but clinical resolution was considered complete in only one of 10 dogs at the end of 21 days.⁴³² Whether pulse therapy with terbinafine might prevent relapse of previously resolved infections remains to be determined, but doubts over skin concentrations achieved with current doses³⁵⁰ makes use of this drug questionable.

Pulsed therapy with itraconazole (5 mg/kg orally once daily, two days on/ five days off for three weeks) has been shown to be efficacious in the treatment of *Malassezia* dermatitis in dogs⁴³⁰ and thus should be effective as a preventative, although one report highlighted potential for development of antifungal drug resistance with pulse dosing (Section 11.5.2³⁸¹). By contrast, this regimen was not fully effective at reducing otic counts of *Malassezia* and therefore pulsed dosing cannot currently be recommended for prevention of otitis externa. There are only anecdotal reports of preventative efficacy of itraconazole for dermatitis at a once-weekly interval. Ketoconazole (5–10 mg/kg orally once daily, two consecutive days per week) has also been recommended anecdotally without any published studies at this dose,⁴⁴⁷ although itraconazole is generally regarded as being a safer drug (See Section 15).

16.4 *Malassezia* Allergen-Specific Immunotherapy

Hyposensitisation to *Malassezia* by immunotherapy was initially proposed in 1998 as an alternative to extended or repeated administration of antifungal drugs in dogs with recurrent *Malassezia* dermatitis with demonstrated IgE to *Malassezia* antigens.²³⁴ In a non peer-reviewed report on *Malassezia* immunotherapy (aqueous extract, 1,000 PNU weekly, Greer Laboratories, Lenoir, GA, USA) added to conventional immunotherapy for other allergens in four dogs with atopic dermatitis still prone to recurrent *Malassezia* dermatitis, results were reported as good to excellent in all cases.⁴⁵⁵ A retrospective study reported a good response to subcutaneous alum-precipitated immunotherapy (Artuvetrin®, 100 µg/mL, ArtuVet Animal Health BV, Lelystad, Netherlands) using 1 mL per month (dose adjusted if required based on clinical response) for a minimum of 10 months. Nine of 16 *Malassezia* monosensitised dogs had an observed reduction in use of both anti-inflammatory and antifungal medication, as well as a >50% reduction in pruritus scores.⁴⁵⁶ However, despite the improvement noted in both studies, the quality of evidence remains low and the significance of >50% improvement of pruritus is disputable as a meaningful measure of success.⁴⁵⁷ Further studies are required to better assess the potential benefits of *Malassezia* allergen-specific immunotherapy as a preventative approach.

16.5 Conclusions

When predisposing factors cannot be controlled, regular treatment is often required to minimise relapses. Topical treatments are preferred to systemic treatments for long-term therapy because of a lower risk of toxicity. Topical prevention of *Malassezia* dermatitis in dogs might be

achieved using 2% chlorhexidine/2% miconazole or 3% chlorhexidine shampoo twice weekly, as has been previously recommended for treatment. Lesser frequencies may be useful in preventing relapse in some cases but there is currently no evidence to support this. Twice weekly topical hydrocortisone aceponate shows promise in the prevention of *Malassezia* otitis externa associated with allergic skin diseases. Pulsed therapy with itraconazole (5 mg/kg orally once daily, two days on/ five days off for three weeks) has been shown to be efficacious in the treatment of *Malassezia* dermatitis (but not otitis externa) in dogs and thus should be effective as a preventative, although one report has highlighted potential for development of antifungal drug resistance with pulse dosing. There are only anecdotal reports of preventative efficacy of itraconazole for dermatitis at a once-weekly interval.

17 *Malassezia* yeasts as zoonotic agents

17.1 Background

Characterizing the zoonotic potential of pathogenic agents is always a difficult task. The concomitant presence of the same species or the same genotypes in humans and animals is a first indication but of course it is not absolute proof unless transmission from one host to another has been clearly demonstrated. The case of *Malassezia* yeasts is rather complex because many of the 18 currently described species have been found on the skin of animals as well as of humans (Table 1).

17.2 Skin colonisation in humans

Several species of *Malassezia* yeast are known to colonize healthy people as part of the commensal microbiome of human skin.^{33,121,458,459} Spatial distributions of the species most commonly identified (*M. globosa*, *M. sympodialis* and *M. restricta*) may vary according to the age, body site and geographical location of the subjects studied.^{88,121,460} The archetypal zoophilic species, *M. pachydermatis*, may also be isolated from healthy human skin by culture or detected by molecular techniques, especially from the face^{460,461} and hands.^{461,462} In a retrospective study of 32 *Malassezia* spp. isolates from human clinical specimens collected in 1984 at the Center for Disease Control in Atlanta (USA) 15 were identified as *M. pachydermatis*.⁴⁶³ These last isolates were mainly from skin, tissue fluids (e.g. eye, ear, vagina) and four were isolated from blood. Skin colonization by *Malassezia* species in full term healthy newborns has been also investigated.⁴⁶⁴ *Malassezia pachydermatis* was not isolated from the skin of human neonates, while *M. sympodialis* and *M. globosa* colonisation begins at birth and increases in the first weeks of life.

17.3 Genotyping

In epidemiological studies, genotyping of *Malassezia* yeasts may be required in order to identify the source of infection and to discover possible connection of genotypes with particular diseases. Different studies targeted various RNA or DNA regions in order to distinguish the molecular pattern of *M. pachydermatis* and to assess whether genotype classification was in accordance with host preferences. In one of these studies, the partial

sequencing of large subunit rRNA in one hundred isolates resulted in the differentiation of seven different haplotypes, namely Ia, Ib, Ic, Id, Ie, If, Ig.³⁰⁰ Haplotypes Ic, Id and Ig seemed to be specific to one animal species (rhinoceros, dogs and ferrets, respectively). Isolates from humans all belonged to haplotype Ia which was also detected in animals (especially dogs and cats). More recently, the spectrum of fungal species ("mycobiome") in the human skin was investigated using next generation sequence techniques.¹²¹ In this study, 14 skin sites representing a range of physiological characteristics were sampled from 10 healthy adult volunteers. *Malassezia* yeasts predominated on most of the sampled body sites and 11 *Malassezia* species (including *M. pachydermatis*) were directly identified by rRNA gene sequencing from the different clinical samples.

17.4 Isolation of *Malassezia pachydermatis* from humans

Pathogenic roles for various *Malassezia* species have been described in association with several human skin diseases including atopic dermatitis, seborrhoeic dermatitis, folliculitis, psoriasis and pityriasis versicolor.^{88,459} Among these diseases, *M. pachydermatis* has been most commonly isolated from human patients with seborrhoeic dermatitis.^{460,465,466} However, it is difficult to assign a truly pathogenic role to *M. pachydermatis* in the context of these studies and its identification from surface samples of human skin is typically ascribed to contact with dogs (even though epidemiological data on pet contact is not always available). One exception has been the report of a facial granuloma in a dog owner, where *M. pachydermatis* was identified by electron microscopy in affected tissues, the yeast was grown and identified by standard microbiological methods and the patient responded to anti-fungal therapy.⁴⁶⁷

Malassezia pachydermatis has also been isolated with significantly higher prevalence from the sputum of asthmatic human patients (21.7%) than from healthy controls (0%).⁴⁶⁸ The clinicopathologic significance of this finding, if any, is unknown and data on pet ownership was not collected from the subjects studied.

17.5 Zoonotic aspects

From a zoonotic perspective, the pathogenic role best documented for *M. pachydermatis* is a syndrome of life-threatening fungaemia that occurs in pre-term neonates while receiving lipid-rich nutritional infusions via catheter.^{469–475} *Malassezia furfur* is the primary skin-colonizing species of human infants⁴⁷⁶ and is therefore the species most commonly implicated in this syndrome;⁴⁷⁷ however *M. pachydermatis* has also been clearly documented as an aetiological agent.⁴⁶⁹ For example, an epidemiological investigation of an outbreak occurring in a neonatal intensive care unit (NICU) identified a single strain of *M. pachydermatis* – as determined by pulsed-field gel electrophoresis – which was isolated from 15 infants with sepsis, nine colonized infants, the hands of a nurse and three dogs owned by other health care workers in the NICU.⁴⁶⁹ In another study, 47 out of 86 *M. pachydermatis* isolates collected from 25 neonatal patients at a French University Hospital were genotyped using intergenic-spacer 1 nucleotide sequence

polymorphisms analysis.⁴⁷¹ All 47 isolates clustered within sequence type 3 (most of them clustered within the 3D subtype, the remaining clustered within three newly described subtypes: 3E, 3F and 3G). No particular subtype was associated with a collection site or a particular time-period but multiple genotypes could colonize the same neonatal patient. The outbreak resolved upon implementation of infection control measures, including withdrawal of lipid-rich hand moisturisers from staff. In addition to this neonatal syndrome, *M. pachydermatis* has been implicated in severe systemic infections of immunocompromised adult patients.^{478,479}

In a study designed to estimate the prevalence of *M. pachydermatis* hand carriage by dog owners, two groups of people were sampled by culture and PCR techniques: owners of 50 healthy dogs and owners of 75 atopic dogs with cytological evidence of *Malassezia dermatitis* and/or otitis.⁴⁶² When detection rates by hand culture were compared, owners of affected dogs were 11 times more likely to be positive for yeast isolation than owners of healthy dogs. However, there was no difference between groups when the highly sensitive PCR technique was utilized, as greater than 90% (70 of 75) of owners in each group had detectable hand carriage.⁴⁶² This study served to underscore the importance of good hand hygiene by health care professionals in whom mechanical carriage of many ubiquitous opportunistic pathogens is possible. Very little is known about hand washing agents and techniques (contact time etc.) that will effectively eliminate carriage of *Malassezia* yeasts from human hands. However, it is known that both chlorhexidine and polyhexanide have excellent *in vitro* activity against *M. pachydermatis*.⁴⁸⁰ In addition, improved hand-washing practices eliminated an endemic problem with *M. pachydermatis* infections in a NICU.⁴⁶⁹

17.6 Conclusions

Given the high prevalence of *M. pachydermatis* hand carriage by dog owners (as assessed by PCR)⁴⁶² and the relative rarity of serious human infections by this organism, it may be surmised that the overall risk for zoonosis is quite low, especially among people who are *not* severely immunocompromised. The need for good hand hygiene by individuals in contact with pet dogs and cats should be emphasised.

Acknowledgements

The authors thank Catherine Outerbridge and Wayne Rosencrantz, co-chairs of the WAVD CCG committee, for facilitating the development of these guidelines.

References

- Moriello KA, Coyner K, Paterson S *et al.* Diagnosis and treatment of dermatophytosis in dogs and cats: Clinical Consensus Guidelines of the World Association for Veterinary Dermatology. *Vet Dermatol* 2017; 28: 266–e68.
- Ebell MH, Siwek J, Weiss BD *et al.* Strength of recommendation taxonomy (SORT): a patient-centered approach to grading evidence in the medical literature. *J Am Board Fam Pract* 2004; 17: 59–67.
- Begerow D, Stoll M, Bauer R. A phylogenetic hypothesis of Ustilaginomycotina based on multiple gene analyses and morphological data. *Mycologia* 2006; 98: 906–916.
- Wang QM, Theelen B, Groenewald M *et al.* Moniliellomycetes and Malasseziomycetes, two new classes in Ustilaginomycotina. *Persoonia* 2014; 33: 41–47.
- Xu J, Saunders CW, Hu P *et al.* Dandruff-associated *Malassezia* genomes reveal convergent and divergent virulence traits shared with plant and human fungal pathogens. *Proc Natl Acad Sci USA* 2007; 104: 18,730–18,735.
- Gioti A, Nystedt B, Li W *et al.* Genomic insights into the atopic eczema-associated skin commensal yeast *Malassezia sympodialis*. *MBio* 2013; 4: e00572–00512.
- Triana S, Gonzalez A, Ohm RA *et al.* Draft genome sequence of the animal and human pathogen *Malassezia pachydermatis* Strain CBS 1879. *Genome Announc* 2015; 3: e01197–15.
- Wu G, Zhao H, Li C *et al.* Genus-wide comparative genomics of *Malassezia* delineates its phylogeny, physiology, and niche adaptation on human skin. *PLoS Genet* 2015; 11: e1005614.
- Boekhout T, Kamp M, Gueho E. Molecular typing of *Malassezia* species with PFGE and RAPD. *Med Mycol* 1998; 36: 365–372.
- Coelho MA, Sampaio JP, Goncalves P. A deviation from the bipolar-tetrapolar mating paradigm in an early diverged basidiomycete. *PLoS Genet* 2010; 6: e1001052.
- Nazzaro-Porro M, Passi S, Caprilli F *et al.* Induction of hyphae in cultures of *Pityrosporum* by cholesterol and cholesterol esters. *J Invest Dermatol* 1977; 69: 531–534.
- Guillot J, Gueho E, Prevost M. Ultrastructural features of the dimorphic yeast *Malassezia furfur*. *J Mycol Med* 1995; 5: 86–91.
- Saadatzadeh MR, Ashbee HR, Holland KT *et al.* Production of the mycelial phase of *Malassezia* in vitro. *Med Mycol* 2001; 39: 487–493.
- Swift JA, Dunbar SF. Ultrastructure of *Pityrosporum ovale* and *Pityrosporum orbiculare*. *Nature* 1965; 206: 1,174–1,175.
- Nishimura K, Asada Y, Tanaka S *et al.* Ultrastructure of budding process of *Malassezia pachydermatis*. *J Med Vet Mycol* 1991; 29: 387–393.
- David M, Gabriel M, Kopecka M. Microtubular and actin cytoskeletons and ultrastructural characteristics of the potentially pathogenic basidiomycetous yeast *Malassezia pachydermatis*. *Cell Biol Int* 2007; 31: 16–23.
- Baillon EH. *Traité de Botanique Médicale Cryptogaminique*. Paris: Doin; 1889.
- Gueho-Kellerman E, Boekhout T, Begerow D *et al.* Biodiversity, phylogeny and ultrastructure. In: Boekhout T, Gueho-Kellerman E, Maysner P *et al.*, eds. *Malassezia and the skin. Science and clinical practice*. Berlin: Springer; 2010: 17–63.
- Simmons RB, Gueho E. A new species of *Malassezia*. *Mycol Res* 1990; 94: 1,146–1,149.
- Guého E, Midgley G, Guillot J. The genus *Malassezia* with description of four new species. *Antonie van Leeuwenhoek* 1996; 69: 337–355.
- Sugita T, Takashima M, Shinoda T *et al.* New yeast species, *Malassezia dermatis*, isolated from patients with atopic dermatitis. *J Clin Microbiol* 2002; 40: 1,363–1,367.
- Sugita T, Takashima M, Kodama M *et al.* Description of a new yeast species, *Malassezia japonica*, and its detection in patients with atopic dermatitis and healthy subjects. *J Clin Microbiol* 2003; 41: 4,695–4,699.
- Sugita T, Tajima M, Takashima M *et al.* A new yeast, *Malassezia yamatoensis*, isolated from a patient with seborrheic dermatitis, and its distribution in patients and healthy subjects. *Microbiol Immunol* 2004; 48: 579–583.
- Hirai A, Kano R, Makimura K *et al.* *Malassezia nana* sp. nov., a novel lipid-dependent yeast species isolated from animals. *Int J Syst Evol Microbiol* 2004; 54: 623–627.
- Cabanes FJ, Theelen B, Castella G *et al.* Two new lipid-dependent *Malassezia* species from domestic animals. *FEMS Yeast Res* 2007; 7: 1,064–1,076.
- Cabanes FJ, Vega S, Castella G. *Malassezia cuniculi* sp. nov., a novel yeast species isolated from rabbit skin. *Med Mycol* 2011; 49: 40–48.

27. Honnavar P, Prasad GS, Ghosh A et al. *Malassezia arunalokei* sp. nov., a novel yeast species isolated from seborrheic dermatitis patients and healthy individuals from India. *J Clin Microbiol* 2016; 54: 1,826–1,834.
28. Cabanes FJ, Coutinho SD, Puig L et al. New lipid-dependent *Malassezia* species from parrots. *Rev Iberoam Micol* 2016; 33: 92–99.
29. Lorch JM, Palmer JM, Vanderwolf KJ et al. *Malassezia versper-tilionis* sp nov.: a new cold-tolerant species of yeast isolated from bats. *Persoonia* 2018; 41: 56–70.
30. Shifrine M, Marr AG. The requirement of fatty acids by *Pity-rosporum Ovale*. *J Gen Microbiol* 1963; 32: 263–270.
31. Guillot J, Guého E, Lesourd M et al. Identification of *Malas-sezia* species. A practical approach. *J Mycol Med* 1996; 6: 103–110.
32. Guillot J, Guého E. The diversity of *Malassezia* yeasts con-firmed by rRNA sequence and nuclear DNA comparisons. *Anto-nie Van Leeuwenhoek* 1995; 67: 297–314.
33. Gaitanis G, Magiatis P, Hantschke M et al. The *Malassezia* genus in skin and systemic diseases. *Clin Microbiol Rev* 2012; 25: 106–141.
34. Kano R, Aizawa T, Nakamura Y et al. Chitin synthase 2 gene sequence of *Malassezia* species. *Microbiol Immunol* 1999; 43: 813–815.
35. Castella G, Coutinho SD, Cabanes FJ. Phylogenetic relation-ships of *Malassezia* species based on multilocus sequence analysis. *Med Mycol* 2014; 52:99–105.
36. Denis J, Machouart M, Morio F et al. Performance of Matrix-Assisted Laser Desorption Ionization-Time of Flight Mass Spec-trometry for Identifying Clinical *Malassezia* Isolates. *J Clin Microbiol* 2017; 55: 90–96.
37. Kolecka A, Khayhan K, Arabatzis M et al. Efficient identification of *Malassezia* yeasts by matrix-assisted laser desorption ioniza-tion-time of flight mass spectrometry (MALDI-TOF MS). *Br J Dermatol* 2014;170: 332–341.
38. Eichstedt E. Pilzbildung in der pityriasis versicolor [Fungal for-mation in pityriasis versicolor]. *Froriep Neue Notiz Natur Heilk* 1846; 39: 270.
39. Robin C. *Histoire naturelle des vegetaux parasites qui croissent sur l'homme et sur les animaux vivants [Natural history of para-sitic plants that grow on humans and living animals]*. Paris: J.B. Baillièrre, 1853; 436–439.
40. Rivolta S. *Dei Parassiti Vegetali: Come Introduzione Allo Studio Delle Malattie Parassitarie E Delle Alterazioni Dell' Alimento Degli Animali Domestici [Plant parasites: an introduction to the study of parasitic diseases and alterations of domestic animal food]*. Torino: Kessinger; 1873: 469–471.
41. Malassez L. Note sur le champignon du pityriasis simple [Note on the fungus of simple pityriasis]. *Arch Physiol* 1874; 1: 451–459.
42. Hay RJ, Midgley G et al. Introduction: *Malassezia* yeasts from a historical perspective. In: Boekhout T, Gueho E, Mayser P, eds. *Malassezia and the skin: science and clinical practice*. Berlin: Springer; 2010: 1–16.
43. Bizzozero J. Über die Mikrophyten der normalen Oberhaut des Menschen [About the microphytes of the normal epidermis of humans]. *Virchow Archiv Pathol Anatomy* 1884; 98: 441–459.
44. Sabouraud RJA. *Maladies du Cuir Chevelu. II. Les Maladies Desquamatives [Scalp Diseases. II. Desquamative Diseases]*. Paris: Masson et Cie, 1904; 1–715.
45. Sabouraud RJA. *Maladies du Cuir Chevelu. III. Maladies cryp-togamiques [Scalp Diseases. III. Cryptogamic Diseases]*. Paris: Masson et Cie, 1910; 1–855.
46. Kraus A. Über das wesen des sogenannten Unnaschen Flaschenbazillus [The nature of the so-called Unna's bottle bacillus]. *Arch Dermatol Syph* 1913; 106: 723–736.
47. Weidman FD. Exfoliative dermatitis in the Indian Rhinoceros (*Rhinoceros unicornis*) with description of a new yeast species, *Pityrosporum pachydermatis*. *Report of the Laboratory Museum Comparative Pathology Zoological Society, Philadel-phia*, 1925; 36–45.
48. MacLeod J, Dowling G. An experimental study of the pity-rosporum of Malassez: its morphology, cultivation and pathogenicity. *Br J Dermatol* 1928; 40: 139–148.
49. Dowling G. Epidermal infectious with yeast-like organisms. *Br Med J* 1929; 2: 947–951.
50. MacLeod J, Dowling G. An experimental study of the pity-rosporum of Malassez: Its morphology, cultivation and pathogenicity. *Brit J Dermatol* 1928; 40: 139–148.
51. Moore M, Kile RL, Engman MF et al. *Pityrosporum ovale* (bottle bacillus of unna, spore of malassez): cultivation and possible role in seborrheic dermatitis. *Arch Dermatol Syph* 1936; 33: 457–472.
52. Lodder J, Kreger-van Rij NJW. *The Yeasts: a taxonomic study*. Amsterdam: North-Holland Publishing Company; 1952: 1–713.
53. Lodder J, Kreger-van Rij NJW. *The Yeasts: a taxonomic study*, 2nd edn. Amsterdam: North-Holland Publishing Company; 1970: 1–1385.
54. Yarrow D, Ahearn D. Genus 7. *Malassezia* Baillon. In: Kre-ger Van Rij NJW, ed. *The-yeasts: A taxonomic study*. 3rd edition. Amsterdam: Elsevier Science Publishers B.V., 1984; 882–885.
55. Cannon PF. International Commision on the Taxonomy of Fungi (ICTF): name changes in fungi of microbiological, industrial and medical importance. Part 2. *Microbiol Sci* 1986; 3: 285–287.
56. Bond R, Anthony RM, Dodd M et al. Isolation of *Malassezia sympodialis* from feline skin. *J Med Vet Mycol* 1996; 34: 145–147.
57. Puig L, Castella G, Cabanes FJ. Cryptic diversity of *Malassezia pachydermatis* from healthy and diseased domestic animals. *Mycopathologia* 2016; 181: 681–688.
58. Gustafson BA. *Otitis externa in the dog. A bacteriological and experimental study*. Stockholm: Gernandts Boktryckeri (Royal Veterinary College thesis). 1955; 117 pp.
59. Sinha BK, Mohapatra LN, Kumar R. Studies on otitis externa in dogs. 1. Survey of aetiological agents: fungi. *Mykosen* 1976; 19: 63–69.
60. Baxter M, Lawler DC. The incidence and microbiology of otitis externa of dogs and cats in New Zealand. *N Z Vet J* 1972; 20: 29–32.
61. Baxter M. The association of *Pityrosporum pachydermatis* with the normal external ear canal of dogs and cats. *J Small Anim Pract* 1976; 17: 231–234.
62. Dufait R. Some cases of canine dermatitis probably due to yeasts (*Candida* and *Pityrosporum*). *Vlaams Diergeneeskundig Tijdschrift* 1975; 44: 92–94.
63. Dufait R. De werking an enkele imidazole verbindingen op *Pity-rosporum canis* [The action of some imidazole compounds on *Pityrosporum canis*]. *Vlaams Diergeneeskundig Tijdschrift* 1981; 50: 99–102.
64. Dufait R. Presence of *Malassezia pachydermatis* (syn. *Pity-rosporum canis*) on the hair and feathers of domestic animals. *Bull Soc Franc Mycol Med* 1985; 14: 19–22.
65. Hajsic M, Tadic V, Lukman P. *Malassezia pachydermatis* in dogs: significance of its location. *Vet Arhiv* 1985; 55: 259–266.
66. Mason KV. Generalised dermatitis associated with *Malassezia pachydermatis* in three dogs. In: *Proceedings of the American Academy of Veterinary Dermatology & American College of Veterinary Dermatology Annual Meeting*. Phoenix, U.S.A. 1987; 35.
67. Mason KV. Seborrheic dermatitis - the aetiology rediscovered. In: *Veterinary Dermatology Newsletter (Proceedings of the British Veterinary Dermatology Study Group)*. Birmingham, U.K. 1992; 6–12.
68. Shuster S. The aetiology of dandruff and the mode of action of therapeutic agents. *Br J Dermatol* 1984; 111: 235–242.
69. Larsson CE, Gandra CRP, Larsson M et al. Dermatitis in dogs caused by *Malassezia (Pityrosporum) pachydermatis*. *Ars Veterinaria* 1988; 4: 63–68.
70. Mason KV, Evans AG. Dermatitis associated with *Malassezia pachydermatis* in 11 dogs. *J Am Anim Hosp Assoc* 1991; 27: 13–20.

71. Pedersen K. Seborrhoeic dermatitis in 10 dogs caused by *Malassezia pachydermatis*. An overlooked problem. *Dansk Veterinærtidsskrift* 1992; 75: 513–520.
72. Mason IS, Mason KV, Lloyd DH. A review of the biology of canine skin with respect to the commensals *Staphylococcus intermedius*, *Demodex canis*, and *Malassezia pachydermatis*. *Vet Dermatol* 1996; 7: 119–132.
73. Hajsig D, Hajsig M, Svoboda VD. *Malassezia pachydermatis* in healthy cats. *Vet Arhiv* 1990; 60: 69–73.
74. Mason KV, Carlotti DN, Miller R. *Malassezia pachydermatis* associated dermatitis in the cat. In: *Proceedings of the American Academy of Veterinary Dermatology & American College of Veterinary Dermatology Annual Meeting*. Charleston, South Carolina: 1994; 83.
75. Guillot J, Chermette R, Guého E. Prevalence of the genus *Malassezia* in the Mammalia. *J de Mycol Medi* 1994; 4: 72–79.
76. Bond R, Howell SA, Haywood PJ *et al.* Isolation of *Malassezia sympodialis* and *Malassezia globosa* from healthy pet cats. *Vet Rec* 1997; 141: 200–201.
77. Crespo MJ, Abarca ML, Cabañes FJ. Isolation of *Malassezia furfur* from a cat. *J Clin Microbiol* 1999; 37: 1,573–1,574.
78. Colombo S, Nardoni S, Cornegliani L *et al.* Prevalence of *Malassezia* spp. yeasts in feline nail folds: a cytological and mycological study. *Vet Dermatol* 2007; 18: 278–283.
79. Hirai A, Kano R, Makimura K *et al.* A unique isolate of *Malassezia* from a cat. *J Vet Med Sci* 2002; 64: 957–959.
80. Åhman S, Perrins N, Bond R. Carriage of *Malassezia* spp. yeasts in healthy and seborrhoeic Devon Rex cats. *Med Mycol* 2007; 45: 449–455.
81. Bond R, Stevens K, Perrins N *et al.* Carriage of *Malassezia* spp. yeasts in Cornish Rex, Devon Rex and Domestic short-haired cats: a cross-sectional survey. *Vet Dermatol* 2008; 19: 299–304.
82. Perrins N, Gaudiano F, Bond R. Carriage of *Malassezia* spp. yeasts in cats with diabetes mellitus, hyperthyroidism and neoplasia. *Med Mycol* 2007; 45: 541–546.
83. Mauldin EA, Morris DO, Goldschmidt MH. Retrospective study: the presence of *Malassezia* in feline skin biopsies. A clinicopathological study. *Vet Dermatol* 2002; 13: 7–13.
84. Cafarchia C, Gallo S, Capelli G *et al.* Occurrence and population size of *Malassezia* spp. in the external ear canal of dogs and cats both healthy and with otitis. *Mycopathologia* 2005; 160: 143–149.
85. Ordeix L, Galeotti F, Scarampella F *et al.* *Malassezia* spp. overgrowth in allergic cats. *Vet Dermatol* 2007; 18: 316–323.
86. Åhman S, Perrins N, Bond R. Treatment of *Malassezia pachydermatis*-associated seborrhoeic dermatitis in Devon Rex cats with itraconazole - a pilot study. *Vet Dermatol* 2007; 18: 171–174.
87. Theelen B, Cafarchia C, Gaitanis G *et al.* *Malassezia* ecology, pathophysiology, and treatment. *Med Mycol* 2018; 56: 10–25.
88. Sugita T, Boekhout T, Velegraki A *et al.* Epidemiology of *Malassezia*-related skin diseases. In: Boekhout T, Gueho-Kellerman E, Mayser P *et al.*, eds. *Malassezia and the skin*. Science and clinical practice. Heidelberg: Springer; 2010: 65–119.
89. Amend A. From dandruff to deep-sea vents: *Malassezia*-like fungi are ecologically hyper-diverse. *PLoS Pathog* 2014; 10: e1004277.
90. Elhady A, Gine A, Topalovic O *et al.* Microbiomes associated with infective stages of root-knot and lesion nematodes in soil. *PLoS ONE* 2017; 12: e0177145.
91. Renker C, Alpei J, Buscot F. Soil nematodes associated with the mammal pathogenic fungal genus *Malassezia* (Basidiomycota: Ustilaginomycetes) in Central European forests. *Biol Fertil Soils* 2003; 37: 70–72.
92. Saijonna-Koulumies LE, Lloyd DH. Colonization of neonatal puppies by *Staphylococcus intermedius*. *Vet Dermatol* 2002; 13: 123–130.
93. Wagner R, Schadler S. Qualitative study of *Malassezia* species colonisation in young puppies. *Vet Rec* 2000; 147: 192–194.
94. Kennis RA, Rosser EJ, Olivier NB *et al.* Quantity and distribution of *Malassezia* organisms on the skin of clinically normal dogs. *J Am Vet Med Assoc* 1996; 208: 1,048–1,051.
95. Pappalardo E, Martino PA, Noli C. Macroscopic, cytological and bacteriological evaluation of anal sac content in normal dogs and in dogs with selected dermatological diseases. *Vet Dermatol* 2002; 13: 315–322.
96. Robson DC, Burton GG, Lorimer MF. Cytological examination and physical characteristics of the anal sacs in 17 clinically normal dogs. *Aust Vet J* 2003; 81: 36–41.
97. Newbold GM, Outerbridge CA, Kass PH *et al.* *Malassezia* spp on the periorcular skin of dogs and their association with blepharitis, ocular discharge, and the application of ophthalmic medications. *J Am Vet Med Assoc* 2014; 244: 1,304–1,308.
98. Bond R, Lloyd DH. Skin and mucosal populations of *Malassezia pachydermatis* in healthy and seborrhoeic basset hounds. *Vet Dermatol* 1997; 8: 101–106.
99. Bond R, Lloyd DH. The effect of topical therapy on *Malassezia pachydermatis*-associated seborrhoeic dermatitis on oral carriage of *Malassezia pachydermatis* in basset hounds. *Vet Rec* 1998; 142: 725–726.
100. Brito EH, Fontenelle RO, Brilhante RS *et al.* The anatomical distribution and antimicrobial susceptibility of yeast species isolated from healthy dogs. *Vet J* 2009; 182: 320–326.
101. Santin R, Mattei AS, Waller SB *et al.* Clinical and mycological analysis of dog's oral cavity. *Braz J Microbiol* 2013; 44: 139–143.
102. Cafarchia C, Gallo S, Romito D *et al.* Frequency, body distribution, and population size of *Malassezia* species in healthy dogs and in dogs with localized cutaneous lesions. *J Vet Diagn Invest* 2005; 17: 316–322.
103. Raabe P, Mayser P, Weiss R. Demonstration of *Malassezia furfur* and *M. sympodialis* together with *M. pachydermatis* in veterinary specimens. *Mycoses* 1998; 41: 493–500.
104. Nardoni S, Mancianti F, Corazza M *et al.* Occurrence of *Malassezia* species in healthy and dermatologically diseased dogs. *Mycopathologia* 2004; 157: 383–388.
105. Bond R, Anthony RM. Characterization of markedly lipid-dependent *Malassezia pachydermatis* isolates from healthy dogs. *J Appl Bacteriol* 1995; 78: 537–542.
106. Puig L, Bragulat MR, Castella G *et al.* Characterization of the species *Malassezia pachydermatis* and re-evaluation of its lipid dependence using a synthetic agar medium. *PLoS ONE* 2017; 12: e0179148.
107. Machado ML, Ferreiro L, Ferreira RR *et al.* *Malassezia* dermatitis in dogs in Brazil: diagnosis, evaluation of clinical signs and molecular identification. *Vet Dermatol* 2011; 22: 46–52.
108. Cafarchia C, Latrofa MS, Figueredo LA *et al.* Physiological and molecular characterization of atypical lipid-dependent *Malassezia* yeasts from a dog with skin lesions: adaptation to a new host? *Med Mycol* 2011; 49: 365–374.
109. Sihelska Z, Vaczi P, Conkova E. Species composition of *Malassezia* yeasts in dogs in Slovakia. *Berl Munch Tierarztl Wochenschr* 2016; 129: 351–354.
110. Cabañes FJ, Hernandez JJ, Castella G. Molecular analysis of *Malassezia sympodialis*-related strains from domestic animals. *J Clin Microbiol* 2005; 43: 277–283.
111. De Bellis F, Castella G, Cabanes FJ *et al.* Absence of DNA sequence diversity of the intergenic spacer 1 region in *Malassezia nana* isolates from cats. *Med Mycol* 2009; 48: 427–429.
112. Castella G, De Bellis F, Bond R *et al.* Molecular characterization of *Malassezia nana* isolates from cats. *Vet Microbiol* 2011; 148: 363–367.
113. Tater KC, Scott DW, Miller WH Jr *et al.* The cytology of the external ear canal in the normal dog and cat. *J Vet Med A Physiol Pathol Clin Med* 2003; 50: 370–374.
114. Pressanti C, Drouet C, Cadiergues MC. Comparative study of aural microflora in healthy cats, allergic cats and cats with systemic disease. *J Feline Med Surg* 2014; 16: 992–996.
115. Åhman SE, Bergstrom KE. Cutaneous carriage of *Malassezia* species in healthy and seborrhoeic Sphynx cats and a

- comparison to carriage in Devon Rex cats. *J Feline Med Surg* 2009; 11: 970–976.
116. Volk AV, Belyavin CE, Varjonen K *et al.* *Malassezia pachydermatis* and *M nana* predominate amongst the cutaneous mycobiota of Sphynx cats. *J Feline Med Surg* 2010; 12: 917–922.
 117. Meason-Smith C, Diesel A, Patterson AP *et al.* Characterization of the cutaneous mycobiota in healthy and allergic cats using next generation sequencing. *Vet Dermatol* 2017; 28: 71–e17.
 118. Meason-Smith C, Diesel A, Patterson AP *et al.* What is living on your dog's skin? Characterization of the canine cutaneous mycobiota and fungal dysbiosis in canine allergic dermatitis. *FEMS Microbiol Ecol* 2015; 91: fiv139.
 119. Gemmer CM, DeAngelis YM, Theelen B *et al.* Fast, noninvasive method for molecular detection and differentiation of *Malassezia* yeast species on human skin and application of the method to dandruff microbiology. *J Clin Microbiol* 2002; 40: 3,350–3,357.
 120. Clavaud C, Jourdain R, Bar-Hen A *et al.* Dandruff is associated with disequilibrium in the proportion of the major bacterial and fungal populations colonizing the scalp. *PLoS ONE* 2013; 8: e58203.
 121. Findley K, Oh J, Yang J *et al.* Topographic diversity of fungal and bacterial communities in human skin. *Nature* 2013; 498: 367–370.
 122. Grice EA, Kong HH, Conlan S *et al.* Topographical and temporal diversity of the human skin microbiome. *Science* 2009; 324: 1,190–1,192.
 123. Leung MH, Chan KC, Lee PK. Skin fungal community and its correlation with bacterial community of urban Chinese individuals. *Microbiome* 2016; 4: 46.
 124. Akaza N, Akamatsu H, Sasaki Y *et al.* Cutaneous *Malassezia* microbiota of healthy subjects differ by sex, body part and season. *J Dermatol* 2010; 37: 786–792.
 125. Oh J, Byrd AL, Park M *et al.* Temporal stability of the human skin microbiome. *Cell* 2016; 165: 854–866.
 126. Cusco A, Belanger JM, Gershony L *et al.* Individual signatures and environmental factors shape skin microbiota in healthy dogs. *Microbiome* 2017; 5: 139.
 127. Cusco A, Sanchez A, Altet L *et al.* Individual Signatures Define Canine Skin Microbiota Composition and Variability. *Front Vet Sci* 2017; 4: 6.
 128. Older CE, Diesel A, Patterson AP *et al.* The feline skin microbiota: The bacteria inhabiting the skin of healthy and allergic cats. *PLoS ONE* 2017; 12: e0178555.
 129. Hort W, Mayser P. *Malassezia* virulence determinants. *Curr Opin Infect Dis* 2011; 24: 100–105.
 130. Ianiri G, Averette AF, Kingsbury JM *et al.* Gene function analysis in the ubiquitous human commensal and pathogen *Malassezia* genus. *MBio* 2016; 7: e01853–16.
 131. Ianiri G, Applen Clancey S, Lee SC *et al.* FKBP12-Dependent Inhibition of Calcineurin Mediates Immunosuppressive Antifungal Drug Action in *Malassezia*. *MBio* 2017; 8: e01752–17.
 132. Celis AM, Vos AM, Triana S *et al.* Highly efficient transformation system for *Malassezia furfur* and *Malassezia pachydermatis* using *Agrobacterium tumefaciens*-mediated transformation. *J Microbiol Methods* 2017; 134: 1–6.
 133. Mittag H. Fine structural investigation of *Malassezia furfur*. II. The envelope of the yeast cells. *Mycoses* 1995; 38: 13–21.
 134. Simmons RB, Ahearn DG. Cell wall ultrastructure and diazonium blue B reaction of *Sporopachydermia quercuum*, *Bullera tsugae*, and *Malassezia* spp. *Mycologia* 1987; 79: 38–43.
 135. Kruppa MD, Lowman DW, Chen YH *et al.* Identification of (1–>6)-beta-D-glucan as the major carbohydrate component of the *Malassezia sympodialis* cell wall. *Carbohydr Res* 2009; 344: 2,474–2,479.
 136. Stalheberger T, Simenel C, Clavaud C *et al.* Chemical organization of the cell wall polysaccharide core of *Malassezia restricta*. *J Biol Chem* 2014; 289: 12,647–12,656.
 137. Simmons RB. Comparison of chitin localization in *Saccharomyces cerevisiae*, *Cryptococcus neoformans* and *Malassezia* spp. *Mycol Res* 1989; 93: 551–553.
 138. Allaker RP, Noble WC. Microbial interactions on skin. In: Noble WC, ed. *The skin microflora and microbial skin disease*. Cambridge: Cambridge University Press; 1992: 331–354.
 139. Li H, Goh BN, Teh WK *et al.* Skin commensal *Malassezia globosa* secreted protease attenuates *Staphylococcus aureus* biofilm formation. *J Invest Dermatol* 2017; 138: 1,137–1,145.
 140. Peleg AY, Hogan DA, Mylonakis E. Medically important bacterial-fungal interactions. *Nat Rev Microbiol* 2010; 8: 340–349.
 141. Gow NA, Hube B. Importance of the *Candida albicans* cell wall during commensalism and infection. *Curr Opin Microbiol* 2012; 15: 406–412.
 142. Aly R, Bibbel DJ. Adherence of skin microorganisms and the development of skin flora from birth. In: Noble WC, ed. *The skin microflora and microbial skin disease*. Cambridge: Cambridge University Press; 1992: 355–372.
 143. Ashbee HR, Bond R. *Malassezia* species and immunity: host-pathogen interactions. In: Boekhout T, Gueho E, Mayser P *et al.*, eds. *Malassezia and the skin*. Science and clinical practice. Heidelberg: Springer, 2010; 139–174.
 144. Kistowska M, Fenini G, Jankovic D *et al.* *Malassezia* yeasts activate the NLRP3 inflammasome in antigen-presenting cells via Syk-kinase signalling. *Exp Dermatol* 2014; 23: 884–889.
 145. Bond R, Rose JF, Ellis JW *et al.* Comparison of two shampoos for treatment of *Malassezia pachydermatis*-associated seborrhoeic dermatitis in Basset Hounds. *J Small Anim Pract* 1995; 36: 99–104.
 146. Rosales MS, Marsella R, Kunkle G *et al.* Comparison of the clinical efficacy of oral terbinafine and ketoconazole combined with cephalixin in the treatment of *Malassezia* dermatitis in dogs—a pilot study. *Vet Dermatol* 2005; 16: 171–176.
 147. Bjerre RD, Bandier J, Skov L *et al.* The role of the skin microbiome in atopic dermatitis: a systematic review. *Br J Dermatol* 2017; 177: 1,272–1,278.
 148. Rodrigues Hoffmann A. The cutaneous ecosystem: the roles of the skin microbiome in health and its association with inflammatory skin conditions in humans and animals. *Vet Dermatol* 2017; 28: 60–e15.
 149. Bradley CW, Morris DO, Rankin SC *et al.* Longitudinal evaluation of the skin microbiome and association with microenvironment and treatment in canine atopic dermatitis. *J Invest Dermatol* 2016; 136: 1,182–1,190.
 150. Schuster M, Schweizer G, Kahmann R. Comparative analyses of secreted proteins in plant pathogenic smut fungi and related basidiomycetes. *Fungal Genet Biol* 2017; 112: 21–30.
 151. Patino-Uzcategui A, Amado Y, Cepero de Garcia M *et al.* Virulence gene expression in *Malassezia* spp from individuals with seborrhoeic dermatitis. *J Invest Dermatol* 2011; 131: 2,134–2,136.
 152. Velegraki A, Cafarchia C, Gaitanis G *et al.* *Malassezia* infections in humans and animals: pathophysiology, detection, and treatment. *PLoS Pathog* 2015; 11: e1004523.
 153. Park M, Cho YJ, Lee YW *et al.* Whole genome sequencing analysis of the cutaneous pathogenic yeast *Malassezia restricta* and identification of the major lipase expressed on the scalp of patients with dandruff. *Mycoses* 2017; 60: 188–197.
 154. Cafarchia C, Dell'Aquila ME, Traversa D *et al.* Expression of the micro-opioid receptor on *Malassezia pachydermatis* and its effect in modulating phospholipase production. *Med Mycol* 2010; 48: 73–78.
 155. Teramoto H, Kumeda Y, Yokoigawa K *et al.* Genotyping and characterisation of the secretory lipolytic enzymes of *Malassezia pachydermatis* isolates collected from dogs. *Vet Rec Open* 2015; 2: e000124.
 156. Cafarchia C, Gasser RB, Latrofa MS *et al.* Genetic variants of *Malassezia pachydermatis* from canine skin: body distribution and phospholipase activity. *FEMS Yeast Res* 2008; 8: 451–459.
 157. Machado ML, Cafarchia C, Otranto D *et al.* Genetic variability and phospholipase production of *Malassezia pachydermatis*

- isolated from dogs with diverse grades of skin lesions. *Med Mycol* 2010; 48: 889–892.
158. Vlachos C, Gaitanis G, Alexopoulos EC *et al.* Phospholipase activity after beta-endorphin exposure discriminates *Malassezia* strains isolated from healthy and seborrhoeic dermatitis skin. *J Eur Acad Dermatol Venereol* 2013; 27: 1575–1578.
 159. Buommino E, Nocera FP, Parisi A *et al.* Correlation between genetic variability and virulence factors in clinical strains of *Malassezia pachydermatis* of animal origin. *New Microbiol* 2016; 39: 216–223.
 160. Figueredo LA, Cafarchia C, Desantis S *et al.* Biofilm formation of *Malassezia pachydermatis* from dogs. *Vet Microbiol* 2012; 160: 126–131.
 161. Angiolella L, Leone C, Rojas F *et al.* Biofilm, adherence, and hydrophobicity as virulence factors in *Malassezia furfur*. *Med Mycol* 2018; 56: 110–116.
 162. Coelho MA, Sampaio JP, Goncalves P. Living and thriving on the skin: *Malassezia* genomes tell the story. *MBio* 2013; 4: e00117-13.
 163. Magiatis P, Pappas P, Gaitanis G *et al.* *Malassezia* yeasts produce a collection of exceptionally potent activators of the Ah (dioxin) receptor detected in diseased human skin. *J Invest Dermatol* 2013; 133: 2,023–2,030.
 164. Buommino E, Baroni A, Papulino C *et al.* *Malassezia pachydermatis* up-regulates AhR related CYP1A1 gene and epidermal barrier markers in human keratinocytes. *Med Mycol* 2018; 56: 987–993.
 165. Kiss G, Radvanyi S, Szigeti G. Characteristics of *Malassezia pachydermatis* strains isolated from canine otitis externa. *Mycoses* 1996; 39: 313–321.
 166. Doekes G, Kaal MJH, van Ieperen-van Dijk AG. Allergens of *Pityrosporum ovale* and *Candida albicans*. II. Physicochemical characterization. *Allergy Copenhagen* 1993; 48: 401–408.
 167. Doekes G, van Ieperen-van Dijk AG. Allergens of *Pityrosporum ovale* and *Candida albicans*. I. Cross-reactivity of IgE-binding components. *Allergy Copenhagen* 1993; 48: 394–400.
 168. Tada Y, Riedl E, Lowenthal MS *et al.* Identification and characterization of endogenous Langerin ligands in murine extracellular matrix. *J Invest Dermatol* 2006; 126: 1,549–1,558.
 169. Tateno H, Ohnishi K, Yabe R *et al.* Dual specificity of Langerin to sulfated and mannosylated glycans via a single C-type carbohydrate recognition domain. *J Biol Chem* 2010; 285: 6,390–6,400.
 170. de Jong MA, Vriend LE, Theelen B *et al.* C-type lectin Langerin is a beta-glucan receptor on human Langerhans cells that recognizes opportunistic and pathogenic fungi. *Mol Immunol* 2010; 47: 1,216–1,225.
 171. Ishikawa T, Itoh F, Yoshida S *et al.* Identification of distinct ligands for the C-type lectin receptors Mincle and Dectin-2 in the pathogenic fungus *Malassezia*. *Cell Host Microbe* 2013; 13: 477–488.
 172. Yamasaki S, Matsumoto M, Takeuchi O *et al.* C-type lectin Mincle is an activating receptor for pathogenic fungus, *Malassezia*. *Proc Natl Acad Sci USA*. 2009; 106: 1,897–1,902.
 173. Grice EA, Dawson TL. Host–microbe interactions: *Malassezia* and human skin. *Curr Opin Microbiol* 2017; 40: 81–87.
 174. Glatz M, Bosshard P, Hoetzenecker W *et al.* The role of *Malassezia* spp. in atopic dermatitis. *J Clin Med* 2015; 4: 1,217–1,228.
 175. Sparber F, LeibundGut-Landmann S. Host Responses to *Malassezia* spp. in the mammalian skin. *Front Immunol* 2017; 8: 1614.
 176. Bond R, Patterson-Kane JC, Lloyd DH. Clinical, histopathological and immunological effects of exposure of canine skin to *Malassezia pachydermatis*. *Med Mycol* 2004; 42: 165–175.
 177. Marsella R. Fixing the skin barrier: past, present and future – man and dog compared. *Vet Dermatol* 2013; 24: 73–e18.
 178. Scheynius A, Johansson C, Buentke E *et al.* Atopic eczema/dermatitis syndrome and *Malassezia*. *Int Arch Allergy Immunol* 2002; 127: 161–169.
 179. Baroni A, Perfetto B, Paoletti I *et al.* *Malassezia furfur* invasiveness in a keratinocyte cell line (HaCat): effects on cytoskeleton and on adhesion molecule and cytokine expression. *Arch Dermatol Res* 2001; 293: 414–419.
 180. Johansson HJ, Vallhov H, Holm T *et al.* Extracellular nanovesicles released from the commensal yeast *Malassezia sympodialis* are enriched in allergens and interact with cells in human skin. *Sci Rep* 2018; 8: 9182.
 181. Ruth Ashbee H. Recent developments in the immunology and biology of *Malassezia* species. *FEMS Immunol Med Microbiol* 2006; 47: 14–23.
 182. Donnarumma G, Paoletti I, Buommino E *et al.* *Malassezia furfur* induces the expression of β -defensin-2 in human keratinocytes in a protein kinase C-dependent manner. *Arch Dermatol Res* 2004; 295: 474–481.
 183. Buentke E, Zargari A, Heffler LC *et al.* Uptake of the yeast *Malassezia furfur* and its allergenic components by human immature CD1a+ dendritic cells. *Clin Exp Allergy* 2000; 30: 1,759–1,770.
 184. Li L, Wang S, Zou Z *et al.* Activation profile of THP-1 derived dendritic cells stimulated by allergen Mal f 1 beyond its IgE-binding ability. *Int Immunopharmacol* 2018; 62: 139–146.
 185. Banchereau J, Steinman RM. Dendritic cells and the control of immunity. *Nature* 1998; 392: 245–252.
 186. Buentke E, Heffler LC, Wilson JL *et al.* Natural killer and dendritic cell contact in lesional atopic dermatitis skin - *Malassezia*-influenced cell interaction. *J Invest Dermatol* 2002; 119: 850–857.
 187. Saadatzadeh MR, Ashbee HR, Cunliffe WJ *et al.* Cell-mediated immunity to the mycelial phase of *Malassezia* spp. in patients with pityriasis versicolor and controls. *Br J Dermatol* 2001; 144: 77–84.
 188. Buentke E, Heffler LC, Wallin RPA *et al.* The allergenic yeast *Malassezia furfur* induces maturation of human dendritic cells. *Clin Exp Allergy* 2001; 31: 1,583–1,593.
 189. Bond R, Elwood CM, Littler RM *et al.* Humoral and cell-mediated responses to *Malassezia pachydermatis* in healthy dogs and dogs with *Malassezia* dermatitis. *Vet Rec* 1998; 143: 381–384.
 190. Morris DO, Clayton DJ, Drobotz KJ *et al.* Response to *Malassezia pachydermatis* by peripheral blood mononuclear cells from clinically normal and atopic dogs. *Am J Vet Res* 2002; 63: 358–362.
 191. Bond R, Curtis CF, Hendricks A *et al.* Intradermal test reactivity to *Malassezia pachydermatis* in atopic dogs. *Vet Rec* 2002; 150: 448–449.
 192. Bond R, Patterson-Kane JC, Perrins N *et al.* Patch test responses to *Malassezia pachydermatis* in healthy basset hounds and in basset hounds with *Malassezia* dermatitis. *Med Mycol* 2006; 44: 419–427.
 193. Rokugo M, Tagami H, Usuba Y *et al.* Contact sensitivity to *Pityrosporum ovale* in patients with atopic dermatitis. *Arch Dermatol* 1990; 126: 627–632.
 194. Savolainen J, Lintu P, Kosonen J. *Pityrosporum* and *Candida* specific and non-specific humoral, cellular and cytokine responses in atopic dermatitis patients. *Clin Exp Allergy* 2001; 31: 125–134.
 195. Tengvall Linder M, Johansson C, Zargari A *et al.* Detection of *Pityrosporum orbiculare* reactive T cells from skin and blood in atopic dermatitis and characterization of their cytokine profiles. *Clin Exp Allergy* 1996; 26: 1,286–1,297.
 196. Tengvall Linder M, Johansson C, Bengtsson A *et al.* *Pityrosporum orbiculare*-reactive T-cell lines in atopic dermatitis patients and healthy individuals. *Scand J Immunol* 1998; 47: 152–158.
 197. Tengvall Linder M, Johansson C, Scheynius A *et al.* Positive atopy patch test reactions to *Pityrosporum orbiculare* in atopic dermatitis patients. *Clin Exp Allergy* 2000; 30: 122–131.
 198. Kroger S, Neuber K, Gruseck E *et al.* *Pityrosporum ovale* extracts increase interleukin-4, interleukin-10 and IgE synthesis in patients with atopic eczema. *Acta Derm Venereol* 1995; 75: 357–360.
 199. Johansson C, Eshaghi H, Linder MT *et al.* Positive Atopy Patch Test Reaction to *Malassezia furfur* in Atopic Dermatitis

- Correlates with a T Helper 2-like Peripheral Blood Mononuclear Cells Response. *J Invest Dermatol* 2002; 118: 1,044–1,051.
200. Sohnle PG, Collins-Lech C, Huhta KE. Class-specific antibodies in young and aged humans against organisms producing superficial fungal infections. *Br J Dermatol* 1983; 108: 69–76.
 201. Bergbrant IM, Faergemann J. Variations of *Pityrosporum orbiculare* in middle-aged and elderly individuals. *Acta Derm-Venerol* 1988; 68: 537–540.
 202. Cunningham AC, Ingham E, Gowland G. Humoral responses to *Malassezia furfur* serovars A, B and C in normal individuals of various ages. *Br J Dermatol* 1992; 127: 476–481.
 203. Bond R, Lloyd DH. Immunoglobulin G responses to *Malassezia pachydermatis* in healthy dogs and dogs with *Malassezia* dermatitis. *Vet Rec* 2002; 150: 509–512.
 204. Broberg A, Faergemann J, Johansson S *et al.* *Pityrosporum ovale* and atopic dermatitis in children and young adults. *Acta Derm Venereol* 1992; 72: 187–192.
 205. Johansson C, Tengvall Linder M, Aalberse RC *et al.* Elevated Levels of IgG and IgG4 to *Malassezia* Allergens in Atopic Eczema Patients with IgE Reactivity to *Malassezia*. *Int Arch Allergy Immunol* 2004; 135: 93–100.
 206. Nuttall TJ, Halliwell RE. Serum antibodies to *Malassezia* yeasts in canine atopic dermatitis. *Vet Dermatol* 2001; 12: 327–332.
 207. Chen TA, Halliwell REW, Hill PB. Immunoglobulin G responses to *Malassezia pachydermatis* antigens in atopic and normal dogs. In: Thoday KL, Foil CS, Bond R, eds. *Advances in Veterinary Dermatology*, volume 4. Oxford: Blackwell Science; 2002: 202–209.
 208. Belew PW, Rosenberg EW, Jennings BR. Activation of the alternative pathway of complement by *Malassezia ovalis* (*Pityrosporum ovale*). *Mycopathologia* 1980; 70: 187–191.
 209. Sohnle PG, Collins-Lech C. Activation of Complement by *Pityrosporum orbiculare*. *J Invest Dermatol* 1983; 80: 93–97.
 210. Nordvall SL, Lindgren L, Johansson SGO *et al.* IgE antibodies to *Pityrosporum orbiculare* and *Staphylococcus aureus* in patients with very high serum total IgE. *Clin Exp Allergy* 1992; 22: 756–761.
 211. Wessels MW, Doekes G, Ieperen-Van Kijk AG *et al.* IgE antibodies to *Pityrosporum ovale* in atopic dermatitis. *Br J Dermatol* 1991; 125: 227–232.
 212. Young E, Koers WJ, Berrens L. Intracutaneous tests with *Pityrosporon* extract in atopic dermatitis. *Acta Derm Venereol* 1989; 144: 122–124.
 213. Nordvall SL, Johansson S. IgE antibodies to *Pityrosporum orbiculare* in children with atopic diseases. *Acta Paediatr Scand* 1990; 79: 343–348.
 214. Mayser P, Gross A. IgE Antibodies to *Malassezia furfur*, *M. sympodialis* and *Pityrosporum orbiculare* in Patients with Atopic Dermatitis, Seborrheic Eczema or Pityriasis Versicolor, and Identification of Respective Allergens. *Acta Derm Venereol* 2000; 80: 357–361.
 215. Zargari A, Midgley G, Bäck O *et al.* IgE-reactivity to seven *Malassezia* species. *Allergy* 2003; 58: 306–311.
 216. Bayrou O, Pecquet C, Flahault A *et al.* Head and neck atopic dermatitis and *Malassezia-furfur*-specific IgE antibodies. *Dermatology* 2005; 211: 107–113.
 217. Zargari A, Eshaghi H, Serum Back O *et al.* IgE Reactivity to *Malassezia furfur* Extract and Recombinant *M. furfur* Allergens in Patients with Atopic Dermatitis. *Acta Derm Venereol* 2001; 81: 418–422.
 218. Jensen-Jarolim E, Poulsen LK, With H *et al.* Atopic dermatitis of the face, scalp, and neck: Type I reaction to the yeast *Pityrosporum ovale*? *J Allergy Clin Immunol* 1992; 89: 44–51.
 219. Johansson S, Karlstrom K. IgE-binding components in *Pityrosporum orbiculare* identified by an immunoblotting technique. *Acta Derm Venereol* 1991; 71: 11–16.
 220. Lintu P, Savolainen J, Kalimo K. IgE antibodies to protein and mannann antigens of *Pityrosporum ovale* in atopic dermatitis patients. *Clin Exp Allergy* 1997; 27: 87–95.
 221. Nissen D, Petersen LJ, Esch R *et al.* IgE-sensitization to cellular and culture filtrates of fungal extracts in patients with atopic dermatitis. *Ann Allergy Asthma Immunol* 1998; 81: 247–255.
 222. Zargari A, Härfast B, Johansson S *et al.* Identification of allergen components of the opportunistic yeast *Pityrosporum orbiculare* by monoclonal antibodies. *Allergy* 1994; 49: 50–56.
 223. Lindborg M, Magnusson CGM, Zargari A *et al.* Selective cloning of allergens from the skin colonizing yeast *Malassezia furfur* by phage surface display technology. *J Invest Dermatol* 1999; 113: 156–161.
 224. Onishi Y, Kuroda M, Yasueda H *et al.* Two-dimensional electrophoresis of *Malassezia* allergens for atopic dermatitis and isolation of Mal f 4 homologs with mitochondrial malate dehydrogenase. *Eur J Biochem* 1999; 261: 148–154.
 225. Rasool O, Zargari A, Almqvist J *et al.* Cloning, characterization and expression of complete coding sequences of three IgE binding *Malassezia furfur* allergens, Mal f 7, Mal f 8 and Mal f 9. *Eur J Biochem* 2000; 267: 4,355–4,361.
 226. Schmidt M, Zargari A, Holt P *et al.* The complete cDNA sequence and expression of the first major allergenic protein of *Malassezia furfur*, Mal f 1. *Eur J Biochem* 1997; 246: 181–185.
 227. Yasueda H, HashidaOkado T, Saito A *et al.* Identification and cloning of two novel allergens from the Lipophilic Yeast, *Malassezia furfur*. *Biochem Biophys Res Commun* 1998; 248: 240–244.
 228. Balaji H, Heratizadeh A, Wichmann K *et al.* *Malassezia sympodialis* thioredoxin-specific T cells are highly cross-reactive to human thioredoxin in atopic dermatitis. *J Allergy Clin Immunol* 2011; 128(1): 92–99.e4.
 229. Layne EA, DeBoer DJ. Serum *Malassezia*-specific IgE in dogs with recurrent *Malassezia* otitis externa without concurrent skin disease. *Vet Immunol Immunopathol* 2016; 176: 1–4.
 230. Chen T-A, Halliwell REW, Pemberton AD *et al.* Identification of major allergens of *Malassezia pachydermatis* in dogs with atopic dermatitis and *Malassezia* overgrowth. *Vet Dermatol* 2002; 13: 141–150.
 231. Barbosa-Lorenzi VC, Peyda S, Scheynius A *et al.* Curdlan induces selective mast cell degranulation without concomitant release of LTC4, IL-6 or CCL2. *Immunobiology* 2017; 222: 647–650.
 232. Kieffer M, Bergbrant I-M, Faergemann J *et al.* Immune reactions to *Pityrosporum ovale* in adult patients with atopic and seborrheic dermatitis. *J Am Acad Dermatol* 1990; 22: 739–742.
 233. Kim YT, Jang IG, Park YM *et al.* Head and neck dermatitis: the role of *Malassezia furfur*, topical steroid use and environmental factors in its causation. *Clin Exp Dermatol* 1999; 24: 226–231.
 234. Morris DO, Olivier NB, Rosser EJ. Type-1 hypersensitivity reactions to *Malassezia pachydermatis* extracts in atopic dogs. *Am J Vet Res* 1998; 59: 836–841.
 235. Morris DO, DeBoer DJ. Evaluation of serum obtained from atopic dogs with dermatitis attributable to *Malassezia pachydermatis* for passive transfer of immediate hypersensitivity to that organism. *Am J Vet Res* 2003; 64: 262–266.
 236. Oldenhoff WE, Frank GR, DeBoer DJ. Comparison of the results of intradermal test reactivity and serum allergen-specific IgE measurement for *Malassezia pachydermatis* in atopic dogs. *Vet Dermatol* 2014; 25: 507–e585.
 237. Bond R, Patterson-Kane JC, Lloyd DH. Intradermal test reactivity to *Malassezia pachydermatis* in healthy basset hounds and basset hounds with *Malassezia* dermatitis. *Vet Rec* 2002; 151: 105–109.
 238. Åberg L, Varjonen K, Åhman S. Results of allergen-specific immunotherapy in atopic dogs with *Malassezia* hypersensitivity: a retrospective study of 16 cases. *Vet Dermatol* 2017; 28: 633–e157.
 239. Santoro D, Marsella R, Pucheu-Haston CM *et al.* Review: Pathogenesis of canine atopic dermatitis: skin barrier and host-micro-organism interaction. *Vet Dermatol* 2015; 26: 84–e25.
 240. Plant JD, Rosenkrantz WS, Griffin CE. Factors associated with a prevalence of high *Malassezia pachydermatis* numbers on dog skin. *J Am Vet Med Assoc* 1992; 201: 879–885.
 241. Bond R, Ferguson EA, Curtis CF *et al.* Factors associated with elevated cutaneous *Malassezia pachydermatis* populations in dogs with pruritic skin disease. *J Small Anim Pract* 1996; 37: 103–107.

242. Mauldin EA, Scott DW, Miller WH *et al.* *Malassezia dermatitis* in the dog: a retrospective histopathological and immunopathological study of 86 cases (1990–95). *Vet Dermatol* 1997; 8: 191–202.
243. Scott DW, Miller WH Jr. Epidermal dysplasia and *Malassezia pachydermatis* infection in West Highland White terriers. *Vet Dermatol* 1989; 1: 25–36.
244. Nardoni S, Dini M, Taccini F *et al.* Occurrence, distribution and population size of *Malassezia pachydermatis* on skin and mucosae of atopic dogs. *Vet Microbiol* 2007; 122: 172–177.
245. Yurayart C, Chindamporn A, Suradhat S *et al.* Comparative analysis of the frequency, distribution and population sizes of yeasts associated with canine seborrheic dermatitis and healthy skin. *Vet Microbiol* 2011; 148: 356–362.
246. Reddy BS, Sivajothi S. Recurrent *Malassezia dermatitis* due to hypothyroidism in a dog and its management. *Comp Clin Pathol* 2016; 25: 531–533.
247. Morris DO. *Malassezia dermatitis*. In: Birchard SJ, Sherding RG, eds. *Saunders's manual of small animal practice*. St. Louis: Saunders Elsevier; 2006: 445–450.
248. Mauldin EA, Crumrine D, Casal ML *et al.* Cellular and metabolic basis for the ichthyotic phenotype in NIPAL4 (Ichthyin)-deficient canines. *Am J Pathol* 2018; 188: 1,419–1,429.
249. Casal ML, Wang P, Mauldin EA *et al.* A defect in NIPAL4 is associated with autosomal recessive congenital ichthyosis in American Bulldogs. *PLoS ONE* 2017; 12: e0170708.
250. Mauldin EA, Wang P, Evans E *et al.* Autosomal recessive congenital ichthyosis in American Bulldogs is associated with NIPAL4 (ICHTHYIN) deficiency. *Vet Pathol* 2015; 52: 654–662.
251. Forster-Van Hijfte MA, Curtis CF, White RN. Resolution of exfoliative dermatitis and *Malassezia pachydermatis* overgrowth in a cat after surgical thymoma resection. *J Small Anim Pract* 1997; 38: 451–454.
252. Jazic E, Coyner KS, Loeffler DG *et al.* An evaluation of the clinical, cytological, infectious and histopathological features of feline acne. *Vet Dermatol* 2006; 17: 134–140.
253. Jenkinson DM. The basis of the skin surface ecosystem. In: Noble WC, ed. *The skin microflora and microbial skin disease*. Cambridge: Cambridge University Press; 1992: 1–32.
254. Sierra P, Guillot J, Jacob H *et al.* Fungal flora on cutaneous and mucosal surfaces of cats infected with feline immunodeficiency virus or feline leukemia virus. *Am J Vet Res* 2000; 61: 158–161.
255. Fraser G. *Pityrosporum pachydermatis* Weidman of canine origin. *Trans Brit Mycol Soc* 1961; 44: 441–448.
256. Nardoni S, Mancianti F, Rum A *et al.* Isolation of *Malassezia* species from healthy cats and cats with otitis. *J Feline Med Surg* 2005; 7: 141–145.
257. Bond R, Saijonmaa Koulumies LEM, Lloyd DH. Population sizes and frequency of *Malassezia pachydermatis* at skin and mucosal sites on healthy dogs. *J Small Anim Pract* 1995; 36: 147–150.
258. Bond R, Collin NS, Lloyd DH. Use of contact plates for the quantitative culture of *Malassezia pachydermatis* from canine skin. *J Small Anim Pract* 1994; 35: 68–72.
259. Crosaz O, Legras A, Vilaplana-Grosso F *et al.* Generalized dermatitis associated with *Malassezia* overgrowth in cats: A report of six cases in France. *Med Mycol Case Rep* 2013; 2: 59–62.
260. Gao Z, Perez-Perez GI, Chen Y *et al.* Quantitation of major human cutaneous bacterial and fungal populations. *J Clin Microbiol* 2010; 48: 3,575–3,581.
261. Noble WC, Somerville DA. *Methods for examining the skin flora*. *Microbiology of human skin*. London: W.B. Saunders, 1974; 316–327.
262. Williamson P, Kligman AM. A new method for the quantitative investigation of cutaneous bacteria. *J Invest Dermatol* 1965; 45: 498–503.
263. Lloyd DH. Evaluation of a cup-scrub technique for quantification of the microbial flora on bovine skin. *J Appl Bacteriol* 1984; 56: 103–107.
264. Dufait R. *Pityrosporon canis* as the cause of canine chronic dermatitis. *Vet Med/Sm Anim Clin* 1983; 78: 1,055–1,057.
265. Keddie F, Orr A, Liebes D. Direct staining on vinyl plastic tape, demonstration of the cutaneous flora of the epidermis by the strip method. *Sabouraudia* 1961; 1: 108–111.
266. Bond R, Sant RE. The recovery of *Malassezia pachydermatis* from canine skin. *Vet Dermatol News* 1993; 15: 25–27.
267. Bensignor E, Jankowski F, Seewald W *et al.* Comparison of two sampling techniques to assess quantity and distribution of *Malassezia* yeasts on the skin of Basset Hounds. *Vet Dermatol* 2002; 13: 237–241.
268. Maynard L, Reme CA, Viaud S. Comparison of two shampoos for the treatment of canine *Malassezia dermatitis*: a randomised controlled trial. *J Small Anim Pract* 2011; 52: 566–572.
269. Faergemann J. The use of contact plates for quantitative culture of *Pityrosporum orbiculare*. *Mycoses* 1987; 30: 298–304.
270. Updegraff DM. A cultural method of quantitatively studying the microorganisms in the skin. *J Invest Dermatol* 1964; 43: 129–137.
271. Wikler JR, Haan Pd, Nieboer C. The 'tape-method': a new and simple method for quantitative culture of *Pityrosporum* yeasts. *Acta Derm Venereol* 1988; 68: 445–449.
272. Wikler JR, Nieboer C, Willemze R. Quantitative skin cultures of *Pityrosporum* yeasts in patients seropositive for the human immunodeficiency virus with and without seborrheic dermatitis. *J Am Acad Dermatol* 1992; 27: 37–39.
273. van Abbe NJ. The investigation of dandruff. *J Soc Cosmetic Chemists* 1964; 15: 609–630.
274. Cox HU, Hoskins JD, Newman SS *et al.* Temporal study of staphylococcal species on healthy dogs. *Am J Vet Res* 1988; 49: 747–751.
275. Hearst BR. Low incidences of staphylococcal dermatitides in animals with high incidence of *Staphylococcus aureus*. *Vet Med/Sm Anim Clin* 1967; 62: 541–542.
276. White SD, Ihrke PJ, Stannard AA *et al.* Occurrence of *Staphylococcus aureus* on the clinically normal canine hair coat. *Am J Vet Res* 1983; 44: 332–334.
277. Mariat F, Adan-Campos C. The carpet technic, a simple method for taking samples from superficial mycosis. *Ann Inst Pasteur (Paris)* 1967; 113: 666–668.
278. Guillot J, Breugnot C, de Barros M *et al.* Usefulness of modified Dixon's medium for quantitative culture of *Malassezia* species from canine skin. *J Vet Diagn Invest* 1998; 10: 384–386.
279. Bond R. *Malassezia pachydermatis* colonisation and infection of canine skin. Royal Veterinary College, PhD thesis. London: University of London; 1996: 215.
280. Bond R, Lloyd D. Comparison of media and conditions of incubation for the quantitative culture of *Malassezia pachydermatis* from canine skin. *Res Vet Sci* 1996; 61: 273–274.
281. Guillot J, Bensignor E, Jankowski F *et al.* Comparative efficacies of oral ketoconazole and terbinafine for reducing *Malassezia* population sizes on the skin of Basset Hounds. *Vet Dermatol* 2003; 14: 153–157.
282. Cavana P, Petit JY, Perrot S *et al.* Efficacy of a 2% climbazole shampoo for reducing *Malassezia* population sizes on the skin of naturally infected dogs. *J Mycol Med* 2015; 25: 268–273.
283. Cavana P, Peano A, Petit JY *et al.* A pilot study of the efficacy of wipes containing chlorhexidine 0.3%, climbazole 0.5% and Tris-EDTA to reduce *Malassezia pachydermatis* populations on canine skin. *Vet Dermatol* 2015; 26: 278–e261.
284. Bensignor E. Treatment of *Malassezia* overgrowth with itraconazole in 15 cats. *Vet Rec* 2010; 167: 1,011–1,012.
285. Mason IS. *Hypersensitivity and the multiplication of staphylococci on canine skin*. Royal Veterinary College, PhD thesis. London: University of London, 1990; 172.
286. Loeffler A, Cobb MA, Bond R. Comparison of a chlorhexidine and a benzoyl peroxide shampoo as sole treatment in canine superficial pyoderma. *Vet Rec* 2012; 169: 249.
287. Kwochka KW, Kowalski JJ. Prophylactic efficacy of four antibacterial shampoos against *Staphylococcus intermedius* in dogs. *Am J Vet Res* 1991; 52: 115–118.
288. Faergemann J, Aly R, Wilson DR *et al.* Skin occlusion: effect on *Pityrosporum orbiculare*, skin Pco₂, pH, transepidermal water

- loss, and water content. *Arch Dermatol Res* 1983; 275: 383–387.
289. Korting HC, Loferer S, Hamm N. The detergent scrub method for quantitative determination of *Malassezia furfur* on chest and back skin: comparative evaluation of three different media. *Mycoses* 1991; 34: 5–6.
 290. Bond R, Lloyd DH, Plummer JM. Evaluation of a detergent scrub technique for the quantitative culture of *Malassezia pachydermatis* from canine skin. *Res Vet Sci* 1995; 58: 133–137.
 291. Allaker RP, Lloyd DH, Smith IM. Prevention of exudative dermatitis in gnotobiotic piglets by bacterial interference. *Vet Rec* 1988; 123: 597–598.
 292. Reuther JWA, Noble WC. An ecological niche for *Staphylococcus saprophyticus*. *Microb Ecol Health Dis* 1993; 6: 209–212.
 293. Allaker RP, Lloyd DH, Bailey RM. Population sizes and frequency of staphylococci at mucocutaneous sites on healthy dogs. *Vet Rec* 1992; 130: 303–304.
 294. White SD, Bourdeau P, Blumstein P *et al.* Comparison via cytology and culture of carriage of *Malassezia pachydermatis* in atopic and healthy dogs. In: Kwochka KW, Willemse T, von Tscharnher C, eds. *Advances in veterinary dermatology*, vol. 3. Oxford: Butterworth Heinemann; 1998: 291–298.
 295. Besignor E, Carlotti DN. Comparaison de differentes techniques cytologiques pour la mise en evidence de *Malassezia pachydermatis* sur la peau du chien [Comparison of different cytological techniques for the diagnosis of *Malassezia pachydermatis* on the skin of the dog]. *Pratique Medicale et Chirurgicale de l'Animal de Compagnie* 1999; 34: 33–41.
 296. Lo KL, Rosenkrantz WS. Evaluation of cytology collection techniques and prevalence of *Malassezia* yeast and bacteria in claw folds of normal and allergic dogs. *Vet Dermatol* 2016; 27: 279–e67.
 297. Omodo-Eluk AJ, Baker KP, Fuller H. Comparison of two sampling techniques for the detection of *Malassezia pachydermatis* on the skin of dogs with chronic dermatitis. *Vet J* 2003; 165: 119–124.
 298. Houghton RH, May JW. Bacteriostasis of *Staphylococcus aureus* by a volatile component of 'Scotch' brand cellulose adhesive tape. *Nature* 1964; 201: 1,346–1,347.
 299. Leeming JP, Notman FH. Improved methods for isolation and enumeration of *Malassezia furfur* from human skin. *J Clin Microbiol* 1987; 25: 2,017–2,019.
 300. Guillot J, Guého E, Chevrier G *et al.* Epidemiological analysis of *Malassezia pachydermatis* isolates by partial sequencing of the large subunit ribosomal RNA. *Res Vet Sci* 1997; 62: 22–25.
 301. Cafarchia C, Stefania Latrofa M, Testini G *et al.* Molecular characterization of *Malassezia* isolates from dogs using three distinct genetic markers in nuclear DNA. *Mol Cell Probes* 2007; 21: 229–238.
 302. Lorenzini R, de Bernardis F. Studies on the isolation, growth and maintenance of *Malassezia pachydermatis*. *Mycopathologia* 1987; 99: 129–131.
 303. Ushijima T, Takahashi M, Ozaki Y. Selective and differential media for isolation and tentative identification of each species of *Pityrosporum* residing on normal or diseased human skin. *Microbiol Immunol* 1981; 25: 1,109–1,118.
 304. Sanguinetti V, Tampieri MP, Morganti L. A survey of 120 isolates of *Malassezia (Pityrosporum) pachydermatis*. Preliminary study. *Mycopathologia* 1984; 85: 1–2.
 305. Bond R, Lloyd D. The relationship between population sizes of *Malassezia pachydermatis* in healthy dogs and in basset hounds with *M. pachydermatis*-associated seborrheic dermatitis and adherence to canine corneocytes in vitro. In: Kwochka K, Willemse T, von Tscharnher C, eds. *Advances in Veterinary Dermatology*, volume 3. Oxford: Butterworth Heinemann, 1998; 284–289.
 306. Bond R, Habibah A, Patterson-Kane JC *et al.* Patch test responses to *Malassezia pachydermatis* in healthy dogs. *Med Mycol* 2006; 44: 175–184.
 307. Bond R, Patterson-Kane JC, Lloyd DH. Intradermal test reactivity to *Malassezia pachydermatis* in healthy basset hounds and bassets with *Malassezia* dermatitis. *Vet Rec* 2002; 151: 105–109.
 308. Boekhout T, Bosboom RW. Karyotyping of *Malassezia* yeasts: taxonomic and epidemiological implications. *Syst Appl Microbiol* 1994; 17: 146–153.
 309. Anthony RM, Howell SA, Lloyd DH *et al.* Application of DNA typing methods to the study of the epidemiology of *Malassezia pachydermatis*. *Microb Ecol Health Dis* 1994; 7: 161–168.
 310. Guillot J, Deville M, Berthelemy M *et al.* A single PCR-restriction endonuclease analysis for rapid identification of *Malassezia* species. *Lett Appl Microbiol* 2000; 31: 400–403.
 311. Cabañes FJ, Theelen B, Castella G *et al.* Two new lipid-dependent *Malassezia* species from domestic animals. *FEMS Yeast Res* 2007; 7: 1,064–1,076.
 312. Gaitanis G, Robert V, Velegraki A. Verifiable single nucleotide polymorphisms of the internal transcribed spacer 2 region for the identification of 11 *Malassezia* species. *J Dermatol Sci* 2006; 43: 214–217.
 313. Sugita T, Takeo K, Hama K *et al.* DNA sequence diversity of intergenic spacer I region in the non-lipid-dependent species *Malassezia pachydermatis* isolated from animals. *Med Mycol* 2005; 43: 21–26.
 314. Koike A, Kano R, Nagata M *et al.* Genotyping of *Malassezia pachydermatis* isolates from canine healthy skin and lesional skin of atopic dermatitis in Japan, Korea and Taiwan. *J Vet Med Sci* 2013; 75: 955–958.
 315. Aizawa T, Kano R, Nakamura Y *et al.* Molecular heterogeneity in clinical isolates of *Malassezia pachydermatis* from dogs. *Vet Microbiol* 1999; 70: 67–75.
 316. Aizawa T, Kano R, Nakamura Y *et al.* The genetic diversity of clinical isolates of *Malassezia pachydermatis* from dogs and cats. *Med Mycol* 2001; 39: 329–334.
 317. Gupta AK, Kohli Y, Summerbell RC. Molecular differentiation of seven *Malassezia* species. *J Clin Microbiol* 2000; 38: 1,869–1,875.
 318. Cafarchia C, Otranto D, Campbell BE *et al.* Multilocus mutation scanning for the analysis of genetic variation within *Malassezia* (Basidiomycota: Malasseziales). *Electrophoresis* 2007; 28: 1,176–1,180.
 319. Ilahi A, Hadrich I, Neji S *et al.* Real-Time PCR Identification of Six *Malassezia* Species. *Curr Microbiol* 2017; 74: 671–677.
 320. Singhal N, Kumar M, Kanaujia PK *et al.* MALDI-TOF mass spectrometry: an emerging technology for microbial identification and diagnosis. *Front Microbiol* 2015; 6: 791.
 321. Drouhet E, Domp Martin D, Papachristou-Moraiti A *et al.* Dermatite experimentale a *Pityrosporum ovale* et (ou) *Pityrosporum orbiculare* chez le cabaye et la souris. *Sabouraudia* 1980; 18: 149–156.
 322. Rosenberg EW, Belew P, Bale G. Effect of topical applications of heavy suspensions of killed *Malassezia ovalis* on rabbit skin. *Mycopathologia* 1980; 72: 147–154.
 323. Faergemann J, Fredriksson T. Experimental infections in rabbits and humans with *Pityrosporum orbiculare* and *P. ovale*. *J Invest Dermatol* 1981; 77: 314–318.
 324. Van Cutsem J, Van Gerven F, Fransen J *et al.* The in vitro antifungal activity of ketoconazole, zinc pyrithione, and selenium sulfide against *Pityrosporum* and their efficacy as a shampoo in the treatment of experimental pityrosporiasis in guinea pigs. *J Am Acad Dermatol* 1990; 22: 993–998.
 325. Schlemmer KB, Jesus FPK, Loreto ES *et al.* An experimental murine model of otitis and dermatitis caused by *Malassezia pachydermatis*. *Mycoses* 2018; 61: 954–958.
 326. Gross TL, Ihrke PJ, Walder EJ *et al.* *Skin diseases of the dog and cat, clinical and histopathologic diagnosis*. 2nd edn. Oxford: Blackwell Publishing; 2005: 142–146.
 327. Olivry T, Hill PB. The ACVD task force on canine atopic dermatitis (XVIII): histopathology of skin lesions. *Vet Immunol Immunopathol* 2001; 81: 305–309.
 328. Bizikova P, Santoro D, Marsella R *et al.* Review: Clinical and histological manifestations of canine atopic dermatitis. *Vet Dermatol* 2015; 26: 79–e24.

329. Velegraki A, Alexopoulos EC, Kritikou S *et al.* Use of fatty acid RPM1 1640 media for testing susceptibilities of eight *Malassezia* species to the new triazole posaconazole and to six established antifungal agents by a modified NCCLS M27–A2 microdilution method and Etest. *J Clin Microbiol* 2004; 42: 3,589–3,593.
330. Cafarchia C, Figueredo LA, Iatta R *et al.* In vitro evaluation of *Malassezia pachydermatis* susceptibility to azole compounds using E-test and CLSI microdilution methods. *Med Mycol* 2012; 50: 795–801.
331. CLSI. Reference method for broth dilution antifungal susceptibility testing of yeasts; approved standard. 3rd edn. CLSI document M27–A3. Wayne, PA: Clinical and Laboratory Standards Institute, 2008.
332. EUCAST Definitive Document E.DEF. 7.3.1. Method for the determination of broth dilution minimum inhibitory concentrations of antifungal agents for yeasts. European Committee on Antimicrobial Susceptibility Testing, 2017. Available at http://www.eucast.org/astoffungi/methodsinantifungalsusceptibilitytesting/susceptibility_testing_of_yeasts Accessed 26/09/2019.
333. Nijima M, Kano R, Nagata M *et al.* An azole-resistant isolate of *Malassezia pachydermatis*. *Vet Microbiol* 2011; 149: 288–290.
334. Cafarchia C, Figueredo LA, Iatta R *et al.* In vitro antifungal susceptibility of *Malassezia pachydermatis* from dogs with and without skin lesions. *Vet Microbiol* 2012; 155: 395–398.
335. Cafarchia C, Figueredo LA, Favuzzi V *et al.* Assessment of the antifungal susceptibility of *Malassezia pachydermatis* in various media using a CLSI protocol. *Vet Microbiol* 2012; 159: 536–540.
336. Alvarez-Perez S, Garcia ME, Pelaez T *et al.* Genotyping and antifungal susceptibility testing of multiple *Malassezia pachydermatis* isolates from otitis and dermatitis cases in pets: is it really worth the effort? *Med Mycol* 2016; 54: 72–79.
337. Peano A, Pasquetti M, Tizzani P *et al.* Methodological issues in antifungal susceptibility testing of *Malassezia pachydermatis*. *J Fungi (Basel)* 2017; 3: 37.
338. Watanabe S, Koike A, Kano R *et al.* In vitro susceptibility of *Malassezia pachydermatis* isolates from canine skin with atopic dermatitis to ketoconazole and itraconazole in East Asia. *J Vet Med Sci* 2014; 76: 579–581.
339. Pasquetti M, Chiavassa E, Agar Tizzani P *et al.* Diffusion Procedures for Susceptibility Testing of *Malassezia pachydermatis*: Evaluation of Mueller-Hinton Agar Plus 2 % Glucose and 0.5 microg/ml Methylene Blue as the Test Medium. *Mycopathologia* 2015; 180: 153–158.
340. Kahlmeter G, Brown DF, Goldstein FW *et al.* European harmonization of MIC breakpoints for antimicrobial susceptibility testing of bacteria. *J Antimicrob Chemother* 2003; 52: 145–148.
341. Peano A, Beccati M, Chiavassa E *et al.* Evaluation of the antifungal susceptibility of *Malassezia pachydermatis* to clotrimazole, miconazole and thiabendazole using a modified CLSI M27–A3 microdilution method. *Vet Dermatol* 2012; 23(131–135): e29.
342. Cafarchia C, Iatta R, Immediato D *et al.* Azole susceptibility of *Malassezia pachydermatis* and *Malassezia furfur* and tentative epidemiological cut-off values. *Med Mycol* 2015; 53: 743–748.
343. Greer ND. Posaconazole (Noxafil): a new triazole antifungal agent. *Proc (Bayl Univ Med Cent)* 2007; 20: 188–196.
344. Weiler CB, de Jesus FP, Nardi GH *et al.* Susceptibility variation of *Malassezia pachydermatis* to antifungal agents according to isolate source. *Braz J Microbiol* 2013; 44: 174–178.
345. Petranyi G, Meingassner JG, Mieth H. Antifungal activity of the allylamine derivative terbinafine in vitro. *Antimicrob Agents Chemother* 1987; 31: 1,365–1,368.
346. Nimura K, Niwano Y, Ishiduka S *et al.* Comparison of in vitro antifungal activities of topical antimycotics launched in 1990s in Japan. *Int J Antimicrob Agents* 1990; 18: 173–178.
347. Leeming JP, Sansom JE, Burton JL. Susceptibility of *Malassezia furfur* subgroups to terbinafine. *Br J Dermatol* 1997; 137: 764–767.
348. Gupta AK, Kohli Y, Li A *et al.* In vitro susceptibility of the seven *Malassezia* species to ketoconazole, voriconazole, itraconazole and terbinafine. *Br J Dermatol* 2000; 142: 758–765.
349. Murai T, Nakamura Y, Kano R *et al.* Susceptibility testing of *Malassezia pachydermatis* using the urea broth microdilution method. *Mycoses* 2002; 45: 84–87.
350. Gimmler JR, White AG, Kennis RA *et al.* Determining canine skin concentrations of terbinafine to guide the treatment of *Malassezia dermatitis*. *Vet Dermatol* 2015; 26: 411–416, e95–96.
351. Nakano Y, Wada M, Tani H *et al.* Effects of beta-thujaplicin on anti-*Malassezia pachydermatis* remedy for canine otitis externa. *J Vet Med Sci* 2005; 67: 1,243–1,247.
352. Odds F. Antifungal therapy. In: Kibbler CC, Mackenzie DWR, Odds F, eds. *Principles and practice of clinical mycology*. Chichester: John Wiley and Sons; 1996: 35–48.
353. Rausch FD, Skinner GW. Incidence and treatment of budding yeasts in canine otitis externa. *Mod Vet Pract* 1978; 59: 914–915.
354. Lorenzini R, Mercantini R, De Bernardis F. In vitro sensitivity of *Malassezia* spp. to various antimycotics. *Drugs Exp Clin Res* 1985; 11: 393–395.
355. Uchida Y, Onodera S, Nakade T *et al.* Sterol composition in polyene antibiotic-sensitive and resistant strains of *Malassezia pachydermatis*. *Vet Res Commun* 1994; 18: 183–187.
356. Chiavassa E, Tizzani P, Peano A. In vitro antifungal susceptibility of *Malassezia pachydermatis* strains isolated from dogs with chronic and acute otitis externa. *Mycopathologia* 2014; 178: 315–319.
357. Lloyd DH, Lamport AI. Activity of chlorhexidine shampoos in vitro against *Staphylococcus intermedius*, *Pseudomonas aeruginosa* and *Malassezia pachydermatis*. *Vet Rec* 1999; 144: 536–537.
358. Guardabassi L, Ghibaud G, Damborg P. In vitro antimicrobial activity of a commercial ear antiseptic containing chlorhexidine and Tris-EDTA. *Vet Dermatol* 2010; 21: 282–286.
359. Young R, Buckley L, McEwan N *et al.* Comparative in vitro efficacy of antimicrobial shampoos: a pilot study. *Vet Dermatol* 2012; 23(1): 36–40, e8.
360. Aspiroz C, Gilaberte Y, Rezusta A *et al.* Gentamycin inhibits the growth of *Malassezia pachydermatis* in culture. *Rev Iberoam Micol* 2010; 27: 20–21.
361. Silva FA, Ferrer O, Deniz S *et al.* In vitro susceptibility testing of *Malassezia pachydermatis* to gentamicin. *Vet Dermatol* 2017; 28: 348–e376.
362. Buommino E, Baroni A, Parisi A *et al.* In vitro growth versus inhibition of growth of *Malassezia pachydermatis* in the presence of the antibacterial drug gentamicin. *J Med Microbiol* 2015; 64: 180–184.
363. Silva FA, Conde-Felipe M, Rosario I *et al.* Susceptibility of *Malassezia pachydermatis* to aminoglycosides. *Mycoses* 2017; 60: 796–799.
364. Carreira A, Ferreira JB, Pereira I *et al.* Blad-containing oligomer: a novel fungicide used in crop protection as an alternative treatment for tinea pedis and tinea versicolor. *J Med Microbiol* 2018; 67: 198–207.
365. Pinheiro AM, Carreira A, Rollo F *et al.* Blad-Containing Oligomer Fungicidal Activity on Human Pathogenic Yeasts. From the Outside to the Inside of the Target Cell. *Front Microbiol* 2016; 7: 1803.
366. Oliveira AMP, Devesa JSP, Hill PB. In vitro efficacy of a honey-based gel against canine clinical isolates of *Staphylococcus pseudintermedius* and *Malassezia pachydermatis*. *Vet Dermatol* 2018; 29: 180–e65.
367. Chen CC, Yan SH, Yen MY *et al.* Investigations of kanuka and manuka essential oils for in vitro treatment of disease and cellular inflammation caused by infectious microorganisms. *J Microbiol Immunol Infect* 2016; 49: 104–111.
368. Khosravi AR, Shokri H, Fahimirad S. Efficacy of medicinal essential oils against pathogenic *Malassezia* sp. isolates. *J Mycol Med* 2016; 26: 28–34.
369. Carrillo-Munoz AJ, Rojas F, Tur-Tur C *et al.* In vitro antifungal activity of topical and systemic antifungal drugs against *Malassezia* species. *Mycoses* 2013; 56: 571–575.

370. Nenoff P, Hausteil UF. In vitro susceptibility testing of *Malassezia furfur* against rilopirox. *Skin Pharmacol* 1997; 10: 275–280.
371. Duarte ER, Hamdan JS. Susceptibility of yeast isolates from cattle with otitis to aqueous solution of povidone iodine and to alcohol-ether solution. *Med Mycol* 2006; 44: 369–373.
372. Sugita T, Tajima M, Tsubuku H *et al.* A new calcineurin inhibitor, pimicrolimus, inhibits the growth of *Malassezia* spp. *Antimicrob Agents Chemother* 2006; 50: 2,897–2,898.
373. Schlemmer KB, de Jesus FPK, Loreto ES *et al.* In vitro combination of antifungal agents against *Malassezia pachydermatis*. *Med Mycol* 2019; 57: 324–327.
374. Alvarez-Perez S, Garcia ME, Blanco JL. In vitro activity of amphotericin B-azole combinations against *Malassezia pachydermatis* strains. *Med Mycol* 2019; 57: 196–203.
375. Kano R, Yokoi S, Kariya N *et al.* Multi-azole-resistant strain of *Malassezia pachydermatis* isolated from a canine *Malassezia* dermatitis. *Med Mycol* 2019; 57: 346–350.
376. Jesus FP, Lautert C, Zanette RA *et al.* In vitro susceptibility of fluconazole-susceptible and -resistant isolates of *Malassezia pachydermatis* against azoles. *Vet Microbiol* 2011; 152: 161–164.
377. Leong C, Buttafuoco A, Glatz M *et al.* Antifungal Susceptibility Testing of *Malassezia* spp. with an Optimized Colorimetric Broth Microdilution Method. *J Clin Microbiol* 2017; 55: 1,883–1,893.
378. Figueredo LA, Cafarchia C, Otranto D. Antifungal susceptibility of *Malassezia pachydermatis* biofilm. *Med Mycol* 2013; 51: 863–867.
379. Sickafoose L, Hosgood G, Snook T *et al.* A noninferiority clinical trial comparing fluconazole and ketoconazole in combination with cephalexin for the treatment of dogs with *Malassezia* dermatitis. *Vet Ther* 2010; 11: E1–13.
380. Yurayart C, Nuchnoul N, Moolkum P *et al.* Antifungal agent susceptibilities and interpretation of *Malassezia pachydermatis* and *Candida parapsilosis* isolated from dogs with and without seborrheic dermatitis skin. *Med Mycol* 2013; 51: 721–730.
381. Angileri M, Pasquetti M, De Lucia M *et al.* Azole resistance of *Malassezia pachydermatis* causing treatment failure in a dog. *Med Mycol Case Rep* 2019; 23: 58–61.
382. Robson D, Moss S, Trott D *et al.* Evidence for possible clinically relevant antifungal resistance in *Malassezia pachydermatis*: 10 cases. In: *Proceedings of the Australian College of Veterinary Scientists Dermatology Chapter Science Week. Gold Coast* 2010; 93–99. Available at <https://ripehosting.blob.core.windows.net/anzcvcs-prod-media/13334/ACVS%20Dermatology%20Chapter%20Proceedings%202010%20Complete.pdf> Accessed September 26, 2019.
383. Bumroongthai K, Chetanachan P, Niyomtham W *et al.* Biofilm production and antifungal susceptibility of co-cultured *Malassezia pachydermatis* and *Candida parapsilosis* isolated from canine seborrheic dermatitis. *Med Mycol* 2016; 54: 544–549.
384. Jerzsele A, Gyetvai B, Csere I *et al.* Biofilm formation in *Malassezia pachydermatis* strains isolated from dogs decreases susceptibility to ketoconazole and itraconazole. *Acta Vet Hung* 2014; 62: 473–480.
385. Brilhante RSN, Rocha MGD, Guedes GMM *et al.* *Malassezia pachydermatis* from animals: Planktonic and biofilm antifungal susceptibility and its virulence arsenal. *Vet Microbiol* 2018; 220: 47–52.
386. Mason KV, Stewart LJ. *Malassezia* and canine dermatitis. In: Ihrke PJ, Mason IS, White SD, eds. *Advances in Veterinary Dermatology*, volume 2. Oxford: Pergamon Press; 1993: 399–402.
387. Mason KV. Cutaneous *Malassezia*. In: Griffin CE, Kwochka KW, MacDonald JM, eds. *Current veterinary dermatology*. St Louis: Mosby Year Book; 1993: 44–48.
388. Guillot J, Bond R. *Malassezia pachydermatis*: a review. *Med Mycol* 1999; 37: 295–306.
389. Chen TA, Hill PB. The biology of *Malassezia* organisms and their ability to induce immune responses and skin disease. *Vet Dermatol* 2005; 16: 4–26.
390. Power HT, Ihrke PJ, Stannard AA *et al.* Use of etretinate for treatment of primary keratinization disorders (idiopathic seborrhea) in cocker spaniels, West Highland White terriers, and basenji hounds. *J Am Vet Med Assoc* 1992; 201: 419–429.
391. Bond R. Superficial veterinary mycoses. *Clin Dermatol* 2010; 28: 226–236.
392. Ravens PA, Xu BJ, Vogelneust LJ. Feline atopic dermatitis: a retrospective study of 45 cases (2001–2012). *Vet Dermatol* 2014; 25: 95–e28.
393. Mason KV. *Malassezia pachydermatis*-associated dermatitis. In: August JR, ed. *Consultations in Feline Internal Medicine*, vol. 3. Philadelphia: W. B. Saunders; 1997: 221–223.
394. Reche A Jr, Daniel AG, Lazaro Strauss TC *et al.* Cutaneous mycoflora and CD4: CD8 ratio of cats infected with feline immunodeficiency virus. *J Feline Med Surg* 2010; 12: 355–358.
395. Bond R, Curtis CF, Ferguson EA *et al.* An idiopathic facial dermatitis of Persian cats. *Vet Dermatol* 2000; 11: 35–41.
396. Fontaine J, Heimann M. Idiopathic facial dermatitis of the Persian cat: three cases controlled with cyclosporine. *Vet Dermatol* 2004; 15(Suppl1): 64 (abstract).
397. Chung TH, Ryu MH, Kim DY *et al.* Topical tacrolimus (FK506) for the treatment of feline idiopathic facial dermatitis. *Aust Vet J* 2009; 87: 417–420.
398. Sharpe SJ, Meadows RL, Senter DA *et al.* Pathology in practice. Liver malignancy and paraneoplastic alopecia in a cat. *J Am Vet Med Assoc* 2014; 244: 1,265–1,267.
399. Marconato L, Albanese F, Viacava P *et al.* Paraneoplastic alopecia associated with hepatocellular carcinoma in a cat. *Vet Dermatol* 2007; 18: 267–271.
400. Tasker S, Griffon DJ, Nuttall TJ *et al.* Resolution of paraneoplastic alopecia following surgical removal of a pancreatic carcinoma in a cat. *J Small Anim Pract* 1999; 40: 16–19.
401. Godfrey DR. A case of feline paraneoplastic alopecia with secondary *Malassezia*-associated dermatitis. *J Small Anim Pract* 1998; 39: 394–396.
402. Grandt LM, Roethig A, Schroeder S *et al.* Feline paraneoplastic alopecia associated with metastasising intestinal carcinoma. *JFMS Open Rep* 2015; 1: 2055116915621582.
403. Caporali C, Albanese F, Binanti D *et al.* Two cases of feline paraneoplastic alopecia associated with a neuroendocrine pancreatic neoplasia and a hepatosplenic plasma cell tumour. *Vet Dermatol* 2016; 27: 508–e137.
404. Pascal-Tenorio A, Olivry T, Gross TL *et al.* Paraneoplastic alopecia associated with internal malignancies in the cat. *Vet Dermatol* 1997; 8: 47–52.
405. Roccabianca P, Rondena M, Paltrinieri S *et al.* Multiple endocrine neoplasia type-I-like syndrome in two cats. *Vet Pathol* 2006; 43: 345–352.
406. Rottenberg S, von Tscherner C, Roosje PJ. Thymoma-associated exfoliative dermatitis in cats. *Vet Pathol* 2004; 41: 429–433.
407. Singh A, Boston SE, Poma R. Thymoma-associated exfoliative dermatitis with post-thymectomy myasthenia gravis in a cat. *Can Vet J* 2010; 51: 757–760.
408. Cavalcanti JV, Moura MP, Monteiro FO. Thymoma associated with exfoliative dermatitis in a cat. *J Feline Med Surg* 2014; 16: 1,020–1,023.
409. Smits B, Reid MM. Feline paraneoplastic syndrome associated with thymoma. *N Z Vet J* 2003; 51: 244–247.
410. Godfrey DR. Dermatitis and associated systemic signs in a cat with thymoma and recently treated with an imidacloprid preparation. *J Small Anim Pract* 1999; 40: 333–337.
411. Patel A, Whitbread TJ, McNeil PE. A case of metabolic epidermal necrosis in a cat. *Vet Dermatol* 1996; 7: 221–226.
412. Day MJ. Review of thymic pathology in 30 cats and 36 dogs. *J Small Anim Pract* 1997; 38: 393–403.
413. Kimmel SE, Christiansen W, Byrnes KP. Clinicopathological, ultrasonographic, and histopathological findings of superficial necrolytic dermatitis with hepatopathy in a cat. *J Am Anim Hosp Assoc* 2003; 39: 23–27.

414. Asakawa MG, Cullen JM, Linder KE. Necrolytic migratory erythema associated with a glucagon-producing primary hepatic neuroendocrine carcinoma in a cat. *Vet Dermatol*. 2013; 24: 466–e110.
415. Gross TL, Ihrke PJ, Walder EJ *et al*. *Skin diseases of the dog and cat. Clinical and histopathologic diagnosis*. 2nd edn. Oxford: Blackwell Science Ltd.; 2005: 86–91.
416. White SD, Bourdeau PB, Blumstein P *et al*. Feline acne and results of treatment with mupirocin in an open clinical trial: 25 cases (1994–96). *Vet Dermatol* 1997; 8: 157–164.
417. Gross TL, Ihrke PJ, Walder EJ *et al*. *Skin diseases of the dog and cat. Clinical and histopathologic diagnosis*. 2nd edn. Oxford: Blackwell Science; 2005: 437–440.
418. Crespo MJ, Abarca ML, Cabañes FJ. Occurrence of *Malassezia* spp. in the external ear canals of dogs and cats with and without otitis externa. *Med Mycol* 2002; 40: 115–121.
419. Crespo MJ, Abarca ML, Cabañes FJ. Otitis externa associated with *Malassezia sympodialis* in two cats. *J Clin Microbiol* 2000; 38: 1,263–1,266.
420. Ginel PJ, Lucena R, Rodriguez JC *et al*. A semiquantitative cytological evaluation of normal and pathological samples from the external ear canal of dogs and cats. *Vet Dermatol* 2002; 13: 151–156.
421. Bollez A, de Rooster H, Furcas A *et al*. Prevalence of external ear disorders in Belgian stray cats. *J Feline Med Surg* 2018; 20: 149–154.
422. Perego R, Proverbio D, Bagnagatti De Giorgi G *et al*. Prevalence of otitis externa in stray cats in northern Italy. *J Feline Med Surg* 2014; 16: 483–490.
423. Mueller RS, Bergvall K, Bensingor E *et al*. A review of topical therapy for skin infections with bacteria and yeast. *Vet Dermatol* 2012; 23: 330–e62.
424. Bensingor E, Hahn H, Guillot J. Topical vs. systemic treatment of *Malassezia dermatitis* in dogs: a comparative, blinded, randomized trial. *Vet Dermatol* 2012; 23: 84 (abstract).
425. Negre A, Bensingor E, Guillot J. Evidence-based veterinary dermatology: a systematic review of interventions for *Malassezia dermatitis* in dogs. *Vet Dermatol* 2009; 20: 1–12.
426. Olivry T, DeBoer DJ, Favrot C *et al*. Treatment of canine atopic dermatitis: 2015 updated guidelines from the International Committee on Allergic Diseases of Animals (ICADA). *BMC Vet Res* 2015; 11: 210.
427. Bensingor E. Oral itraconazole as a pulse therapy for the treatment of canine *Malassezia dermatitis*: a randomized, blinded, comparative trial. *Pratique Médicale et Chirurgicale de l'Animal de Compagnie* 2006; 41: 69–72.
428. Bensingor E. Comparaison de deux posologies de kétoconazole pour le traitement de la dermatite à *Malassezia* chez le chien [Comparison of two ketoconazole dosages for the treatment of *Malassezia dermatitis* in dogs]. *Annales de Médecine Vétérinaire* 2001; 145: 311–316.
429. Mayer UK, Glos K, Schmid M *et al*. Adverse effects of ketoconazole in dogs—a retrospective study. *Vet Dermatol* 2008; 19: 199–208.
430. Pinchbeck LR, Hillier A, Kowalski JJ *et al*. Comparison of pulse administration versus once daily administration of itraconazole for the treatment of *Malassezia pachydermatis dermatitis* and otitis in dogs. *J Am Vet Med Assoc* 2002; 220: 1,807–1,812.
431. Pierard GE, Arrese JE, Pierard-Franchimont C. Itraconazole corneofungimetry bioassay on *Malassezia* species. *Mycoses* 2004; 47: 418–421.
432. Berger DJ, Lewis TP, Schick AE *et al*. Comparison of once-daily versus twice-weekly terbinafine administration for the treatment of canine *Malassezia dermatitis* - a pilot study. *Vet Dermatol* 2012; 23: 418–e479.
433. Chen C. The use of terbinafine for the treatment of dermatophytosis. *Vet Dermatol* 2000; 11: 41 (abstract).
434. Sakai MR, May ER, Imerman PM *et al*. Terbinafine pharmacokinetics after single dose oral administration in the dog. *Vet Dermatol* 2011; 22: 528–534.
435. Bourdeau P, Bruet V, Roussel A *et al*. Comparative efficacy of two shampoos containing an azole derivative to decrease clinical signs and *Malassezia pachydermatis* counts in basset hounds : a comparative blinded, randomized trial. *Vet Dermatol* 2011; 22: 467 (abstract).
436. Marsella R, Nicklin CE, Nerbonne J. Double-blind, placebo-controlled study to evaluate two miconazole conditioners for the treatment of *Malassezia dermatitis* in dogs. *Vet Ther* 2000; 1: 141–149.
437. Carlotti DN, Laffort-Dassot C. Dermatite à *Malassezia* chez le chien : étude bibliographique et rétrospective de 12 cas généralisés traités par des dérivés azolés [Malassezia Dermatitis in Dogs: A literature review and retrospective study of 12 generalized cases treated with azole derivatives]. *Pratique Médicale et Chirurgicale de l'Animal de Compagnie* 1996; 31: 297–307.
438. Nardoni S, Mugnaini L, Pistelli L *et al*. Clinical and mycological evaluation of an herbal antifungal formulation in canine *Malassezia dermatitis*. *J Mycol Med* 2014; 24: 234–240.
439. Reme CA, Cadot P, Holzapfel G *et al*. Efficacy of combined topical therapy with keratoregulating shampoo and lotion in the management of keratoseborrheic disorders associated with *Malassezia proliferation* in dogs. *Vet Dermatol* 2003; 14: 264 (abstract).
440. Mawby DI, Whittemore JC, Genger S *et al*. Bioequivalence of orally administered generic, compounded, and innovator-formulated itraconazole in healthy dogs. *J Vet Intern Med* 2014; 28: 72–77.
441. Mawby DI, Whittemore JC, Fowler LE *et al*. Comparison of absorption characteristics of oral reference and compounded itraconazole formulations in healthy cats. *J Am Vet Med Assoc* 2018; 252: 195–200.
442. Renschler J, Albers A, Sinclair-Mackling H *et al*. Comparison of compounded, generic, and innovator-formulated itraconazole in dogs and cats. *J Am Anim Hosp Assoc* 2018; 54: 195–200.
443. Molter CM, Zuba JR, Papendick R. *Cryptococcus gattii* osteomyelitis and compounded itraconazole treatment failure in a Pesquet's parrot (*Psittirichas fulgidus*). *J Zoo Wildl Med* 2014; 45: 127–133.
444. Smith JA, Papich MG, Russell G *et al*. Effects of compounding on pharmacokinetics of itraconazole in black-footed penguins (*Spheniscus demersus*). *J Zoo Wildl Med* 2010; 41: 487–495.
445. Laporte CM, Cruz-Espindola C, Thungrat K *et al*. Quality assessment of fluconazole capsules and oral suspensions compounded by pharmacies located in the United States. *Am J Vet Res* 2017; 78: 421–432.
446. Chlorhexidine Peltonen L. In: Rowe RC, Sheskey PJ, Quinn ME, eds. *Handbook of pharmaceutical excipients*. 6th edn. London: Pharmaceutical Press and the American Pharmacists Association; 2009: 162–166.
447. Morris D. *Malassezia dermatitis* and otitis. *Vet Clin North Am Small Anim Pract* 1999; 29: 1,303–1,310.
448. Petit JY, Cavana P, Thoumire S *et al*. Use of a modified hair strand test to assess the antifungal activity kinetics of dog hair after a 2% climbazole shampoo application. *Vet Dermatol* 2016; 27: 148–e38.
449. Peano A, Gallo MG. Management of *Malassezia*-related diseases in the dog. *Parassitologia* 2008; 50: 85–88.
450. Olivry T, DeBoer DJ, Favrot C *et al*. Treatment of canine atopic dermatitis: 2010 clinical practice guidelines from the International Task Force on Canine Atopic Dermatitis. *Vet Dermatol* 2010; 21: 233–248.
451. Swinney A, Fazakerley J, McEwan N *et al*. Comparative in vitro antimicrobial efficacy of commercial ear cleaners. *Vet Dermatol* 2008; 19: 373–379.
452. Mason CL, Steen SI, Paterson S *et al*. Study to assess in vitro antimicrobial activity of nine ear cleaners against 50 *Malassezia pachydermatis* isolates. *Vet Dermatol*. 2013; 24: 362–366, e80–81.

453. Bensignor E, Pattyn J, Renme C. Reduction of relapses of recurrent otitis externa in atopic dogs with twice-weekly topical application of hydrocortisone aceponate in the ear canal; a randomized, blinded, controlled study. *Vet Dermatol* 2012; 23 (Supp 1): 92 (abstract).
454. Bassett RJ, Burton GG, Robson DC *et al.* Efficacy of an acetic acid/boric, acid ear cleaning solution for treatment and prophylaxis of *Malassezia* sp. otitis externa. *Aust Vet Pract* 2004; 34: 79–82.
455. Morris DO. *Malassezia* infections. In: Bonagura JD, Twedt DC, eds. *Kirk's current veterinary therapy XV*. St Louis: Elsevier Saunders; 2014: 453–457.
456. Aberg L, Varjonen K, Ahman S. Results of allergen-specific immunotherapy in atopic dogs with *Malassezia* hypersensitivity: a retrospective study of 16 cases. *Vet Dermatol* 2017; 28: 633–e157.
457. Rybníček J, Lau-Gillard PJ, Harvey R *et al.* Further validation of a pruritus severity scale for use in dogs. *Vet Dermatol* 2009; 20: 115–122.
458. White TC, Findley K, Dawson TL Jr *et al.* Fungi on the skin: dermatophytes and *Malassezia*. *Cold Spring Harb Perspect Med* 2014; 4: 019802.
459. Prohic A, Jovicic Sadikovic T, Krupalija-Fazlic M *et al.* *Malassezia* species in healthy skin and in dermatological conditions. *Int J Dermatol* 2016; 55: 494–504.
460. Nakabayashi A, Sei Y, Guillot J. Identification of *Malassezia* species isolated from patients with seborrhoeic dermatitis, atopic dermatitis, pityriasis versicolor and normal subjects. *Med Mycol* 2000; 38: 337–341.
461. Bandhaya M. The distribution of *Malassezia furfur* and *Malassezia pachydermatis* on normal human skin. *Southeast Asian J Trop Med Public Health* 1993; 24: 343–346.
462. Morris DO. *Malassezia pachydermatis* carriage in dog owners. *Emerg Infect Dis* 2005; 11: 83–88.
463. Guého E, Simmons RB, Pruitt WR *et al.* Association of *Malassezia pachydermatis* with systemic infections of humans. *J Clin Microbiol* 1987; 25: 1,789–1,790.
464. Bernier V, Weill FX, Hirigoyen V *et al.* Skin colonization by *Malassezia* species in neonates: a prospective study and relationship with neonatal cephalic pustulosis. *Arch Dermatol* 2002; 138: 215–218.
465. Zarei-Mahmoudabadi A, Zarrin M, Mehdinezhad F. Seborrheic dermatitis due to *Malassezia* species in Ahvaz, Iran. *Iran J Microbiol* 2013; 5: 268–271.
466. Sosa Mde L, Rojas F, Mangiaterra M *et al.* Prevalence of *Malassezia* species associated with seborrheic dermatitis lesions in patients in Argentina. *Rev Iberoam Micol* 2013; 30: 239–242.
467. Fan YM, Huang WM, Li SF *et al.* Granulomatous skin infection caused by *Malassezia pachydermatis* in a dog owner. *Arch Dermatol* 2006; 142: 1,181–1,184.
468. van Woerden HC, Gregory C, Brown R *et al.* Differences in fungi present in induced sputum samples from asthma patients and non-atopic controls: a community based case control study. *BMC Infect Dis* 2013; 13: 69.
469. Chang HJ, Miller HL, Watkins N *et al.* An epidemic of *Malassezia pachydermatis* in an intensive care nursery associated with colonization of health care workers' pet dogs. *N Engl J Med* 1998; 338: 706–711.
470. Chryssanthou E, Broberger U, Petrini B. *Malassezia pachydermatis* fungaemia in a neonatal intensive care unit. *Acta Paediatr* 2001; 90: 323–327.
471. Ilahi A, Hadrich I, Goudjil S *et al.* Molecular epidemiology of a *Malassezia pachydermatis* neonatal unit outbreak. *Med Mycol* 2018; 56: 69–77.
472. Larocco M, Dorenbaum A, Robinson A *et al.* Recovery of *Malassezia pachydermatis* from eight infants in a neonatal intensive care nursery: clinical and laboratory features. *Pediatr Inf Dis J* 1988; 7: 398–401.
473. Mickelsen PA, Viano-Paulson MC, Stevens DA *et al.* Clinical and microbiological features of infection with *Malassezia pachydermatis* in high-risk infants. *J Infect Dis* 1988; 157: 1,163–1,168.
474. van Belkum A, Boekhout T, Bosboom R. Monitoring spread of *Malassezia* infections in a neonatal intensive care unit by PCR-mediated genetic typing. *J Clin Microbiol* 1994; 32: 2,528–2,532.
475. Welbel SF, McNeil MM, Pramanik A *et al.* Nosocomial *Malassezia pachydermatis* bloodstream infections in a neonatal intensive care unit. *Pediatr Infect Dis J* 1994; 13: 104–108.
476. Prohic A, Simic D, Sadikovic TJ *et al.* Distribution of *Malassezia* species on healthy human skin in Bosnia and Herzegovina: correlation with body part, age and gender. *Iran J Microbiol* 2014; 6: 253–262.
477. Dankner WM, Spector SA, Fierer J *et al.* *Malassezia* fungemia in neonates and adults: complication of hyperalimentation. *Rev Infect Dis* 1987; 9: 743–753.
478. Lautenbach E, Nachamkin I, Schuster MG. *Malassezia pachydermatis* infections. *N Engl J Med* 1998; 339: 270.
479. Choudhury S, Marte RL. *Malassezia pachydermatis* fungaemia in an adult on posaconazole prophylaxis for acute myeloid leukaemia. *Pathology (Phila)* 2014; 46: 466–467.
480. Banovic F, Bozic F, Lemo N. In vitro comparison of the effectiveness of polihexanide and chlorhexidine against canine isolates of *Staphylococcus pseudintermedius*, *Pseudomonas aeruginosa* and *Malassezia pachydermatis*. *Vet Dermatol* 2013; 24: 409–413, e88–89.
481. Kumar A, Singh K, Sharma A. Treatment of dermatitis in dogs associated with *Malassezia pachydermatis*. *Indian Vet J* 2002; 79: 730–732.

Supporting Information

Additional Supporting Information may be found in the online version of this article.

Figure S1. Schematic structure of the ribosomal RNA gene in fungi.

Figure S2. Sequencing identification for biological classification level in fungi on each rDNA region.

Table S1. Phenotypic characterization of the 18 currently described *Malassezia* species.

Table S2. Frequency of isolation (%) of *Malassezia pachydermatis* from skin and mucosal sites in selected studies of healthy dogs of varying breeds.

Table S3. The association between *Malassezia* spp. and systemic disease in the cat.

Table S4. The histopathological features of skin diseases where *Malassezia* spp. are likely to be observed in the stratum corneum.

Table S5. Summary of reports on susceptibility testing of *Malassezia pachydermatis* using the broth microdilution method.

Table S6. Summary of reports on susceptibility testing of *Malassezia pachydermatis* using the E-test.

Table S7. Case series of *Malassezia* dermatitis in cats treated with oral itraconazole.

Table S8. Evidence for management of underlying disease for the prevention of *Malassezia* overgrowth.

Résumé

Contexte – Le genre *Malassezia* est composé qu'un groupe de levures lipophiliques qui ont évoluées en tant que commensaux de la peau et pathogènes cutanés opportunistes chez de nombreux mammifères et oiseaux.

Objectifs – L'objectif de ce document est de fournir à la communauté vétérinaire et aux parties intéressées toute l'information actuelle sur l'écologie, la pathophysiologie, le diagnostic, le traitement et la prévention des maladies cutanées associées aux levures *Malassezia* chez le chien et le chat.

Matériel et methods – Les auteurs ont formé un groupe d'experts (GP) et ont revu la littérature disponible avant octobre 2018. Les GP ont préparé une revue de la littérature détaillée et des recommandations ont été faites sur des sujets choisis. Le comité de recommandations de consensus clinique de la WAVD (World Association of Veterinary Dermatology) a fournit des indications et a supervisé le processus. Le document a été présenté à deux congrès internationaux de société de dermatologie vétérinaire et à un workshop international de mycologie ; il était disponible pour tout commentaire sur le site de la WAVD pendant six mois. Les commentaires étaient partagés avec le GP par voie dématérialisée et les réponses, incorporées au document final.

Conclusions et importance Clinique – Il y a eu un développement remarquable des connaissances sur les levures *Malassezia* et leur rôle dans les maladies animales, particulièrement depuis le début des années 1990. La dermatite à *Malassezia* chez le chien et le chat a évolué d'une maladie obscure et controversée sur son existence même, à désormais une maladie diagnostiquée en routine en pratique vétérinaire générale. Les signes cliniques sont bien reconnus et les approches diagnostiques sont bien développées. Une série de traitements topiques et systémiques est connue pour être efficace en particulier quand des facteurs prédisposant sont identifiés et corrigés.

RESUMEN

Introducción – el género *Malassezia* está compuesto por un grupo de levaduras lipofílicas que han evolucionado como comensales cutáneos y patógenos cutáneos oportunistas de una variedad de mamíferos y aves.

Objetivos – el objetivo de este documento es proporcionar a la comunidad veterinaria y otras personas interesadas información actualizada sobre la ecología, la fisiopatología, el diagnóstico, el tratamiento y la prevención de enfermedades de la piel asociadas con las levaduras *Malassezia* en perros y gatos.

Métodos y material – los autores sirvieron como Panel de Orientación (GP) y revisaron la literatura disponible hasta octubre de 2018. El GP preparó una revisión detallada de la literatura e hizo recomendaciones sobre temas seleccionados. El Comité de Pautas de Consenso Clínico de la Asociación Mundial de Dermatología Veterinaria (WAVD) proporcionó orientación y supervisión para este proceso. El documento fue presentado en dos reuniones internacionales de sociedades de dermatología veterinaria y un taller internacional de micología; estuvo disponible para comentarios en el sitio web de WAVD por un período de seis meses. Los comentarios se compartieron electrónicamente con el GP y las respuestas se incorporaron al documento final.

Conclusiones e importancia clínica – ha habido una notable expansión en el conocimiento sobre las levaduras *Malassezia* y su papel en las enfermedades de animales, particularmente desde principios de los años noventa. La dermatitis por *Malassezia* en perros y gatos ha evolucionado de una enfermedad poco clara y de existencia controvertida, a ser ahora un diagnóstico de rutina en la práctica veterinaria general. Los signos clínicos están bien reconocidos y los enfoques de diagnóstico están bien desarrollados. Se conoce una variedad de terapias tópicas y sistémicas efectivas, especialmente cuando se identifican y corrigen los factores predisponentes.

Zusammenfassung

Hintergrund – Die Gattung *Malassezia* besteht aus einer Gruppe von lipophilen Hefen, die sich als Hautkommensalen und als opportunistische kutane Pathogene einer Vielfalt von Säugetieren und Vögeln entwickelt haben.

Ziele – Das Ziel dieses Dokuments war es, die veterinärmedizinische Gesellschaft und andere InteressentInnen mit der gängigen Information über die Ökologie, Pathophysiologie, Diagnose, Behandlung und Vorbeugung von Hauterkrankungen im Zusammenhang mit *Malassezia* Hefen bei Hunden und Katzen zu informieren.

Methoden und Materialien – Die AutorInnen wirkten als Guideline Panel (GP) und führten eine Review der Literatur durch, die vor Oktober 2018 zur Verfügung stand. Die GP erstellten eine detaillierte Literaturretrospektive und machten Empfehlungen über ausgewählte Themen. Die World Association for Veterinary Dermatology (WAVD) Clinical Consensus Guideline Komitee stellte für diesen Prozess die Führung und Aufsicht zur Verfügung. Das erstellte Dokument wurde bei zwei internationalen Treffen der veterinärdermatologischen Vereinigungen sowie bei einem internationalen Mykologie Workshop präsentiert; es wurde auf der WAVD Website für Kommentare für eine Dauer von sechs Monaten zur Verfügung gestellt. Die

Kommentare wurden dem GP elektronisch mitgeteilt und die Antworten in das Enddokument inkludiert.

Schlussfolgerungen und klinische Bedeutung – Das Wissen über *Malassezia* Hefen und ihrer Rolle bei Krankheiten von Tieren hat sich bemerkenswert erweitert, vor allem seit den frühen 1990ern. Die Malasseziendermatitis bei Hunden und Katzen hat sich von einer obskuren Erkrankung mit Kontroversen in Bezug auf ihre Existenz zu einer heute routinemäßigen Diagnose in der allgemeinen Veterinärpraxis entwickelt. Die klinischen Zeichen sind gut bekannt und diagnostische Herangehensweisen gut entwickelt. Eine Breite von topischen und systemischen Therapien ist als wirksam bekannt, vor allem wenn prädisponierende Faktoren identifiziert und korrigiert werden.

要約

背景 – マラセチア属は、さまざまな哺乳類や鳥類の皮膚共生生物および日和見皮膚病原体として進化した親油性酵母のグループで構成されている。

目的 – 本研究の目的は、犬や猫のマラセチア酵母に関連する皮膚疾患の生態学、病態生理学、診断、治療、予防に関する最新情報を獣医コミュニティやその他の関係者に提供することである。

材料と方法 – 著者はガイドラインパネル (GP) を務め、2018年10月より前に入手可能な文献をレビューしました。GPは詳細な文献レビューを作成し、選択したトピックに関する推奨事項を作成した。世界獣医皮膚科学協会 (WAVD) 臨床コンセンサスガイドライン委員会は、このプロセスの指導と監督を提供した。本文書は、獣医皮膚学会の2つの国際会議と1つの国際真菌学ワークショップで発表された。6か月間、WAVDのWebサイトでコメントできるようになった。コメントはGPと電子的に共有され、回答は最終文書に組み込まれた。

結論と臨床的重要性 – 特に1990年代初頭以降、マラセチア酵母と動物疾患におけるそれらの役割に関する知識が著しく拡大した。犬および猫のマラセチア皮膚炎は、その存在があいまいで論争的的となっている病気から、現在では一般的な獣医診療での日常的な診断へと進化している。臨床徴候はよく認識されており、診断アプローチは十分に開発されている。さまざまな局所および全身療法は、特に素因を特定して修正する場合に効果的であることが知られている。

摘要

背景 – 马拉色菌属是由一群亲脂酵母菌组成，这些酵母菌进化为多种哺乳动物和鸟类的皮肤共生菌和皮肤条件致病菌。

目的 – 本文章旨在向兽医界和其他对此有兴趣的群体，提供犬、猫马拉色菌性皮肤病的生态学、病理生理学、诊断、治疗和预防的最新信息。

方法和材料 – 作者们成立指导小组(GP)，回顾了2018年10月之前现存的文献。指导小组编写了详细的文献综述，并就选定的主题提出了建议。世界兽医皮肤病协会(WAVD)临床共识指导委员会为这一过程提供指导和监督。该文件在两个国际兽医皮肤病学会会议和一个国际真菌学研讨会上提出;发表在WAVD网站上提供长达6个月的评论期。GP的评论以电子方式分享，并将答复纳入文件的最终版本。

结论与临床意义 – 对马拉色菌及其在动物疾病中作用的认知得到了显著扩展，自1990年代初以来尤其明显。犬、猫马拉色菌性皮炎从一种默默无闻且存在争议的疾病，到目前已成为全科兽医临床的常规诊断。临床症状易识别，诊断方法也很成熟。已知很多种外部和全身治疗对其有效，特别当易感病因被识别和纠正时。

Resumo

Contexto – O gênero *Malassezia* é composto por um grupo de leveduras lipofílicas que evoluíram como comensais de pele e patógenos cutâneos oportunistas de uma variedade de mamíferos e aves.

Objetivos – O objetivo deste documento é fornecer à comunidade veterinária e outros grupos interessados informações atualizadas sobre ecologia, fisiopatologia, diagnóstico, tratamento e prevenção de doenças de pele associadas à *Malassezia* em cães e gatos.

Métodos e materiais – Os autores serviram como Painel de Diretrizes (GP) e revisaram a literatura disponível antes de outubro de 2018. O GP preparou uma revisão detalhada da literatura e fez recomendações sobre os tópicos selecionados. O comitê de diretrizes de consenso clínico da Associação Mundial de Dermatologia Veterinária (WAVD) forneceu orientações e supervisão para esse processo. O documento foi apresentado em duas reuniões internacionais de sociedades de dermatologia veterinária e em um curso internacional de micologia; foi disponibilizado para comentários no site da WAVD por um período de seis meses. Os comentários foram compartilhados eletronicamente com o GP e as respostas incorporadas no documento final.

Conclusões e importância clínica – Houve uma expansão notável do conhecimento sobre leveduras do gênero *Malassezia* e seu papel na doença animal, principalmente desde o início dos anos 90. A dermatite por *Malassezia* em cães e gatos evoluiu de uma doença em que a sua existência permanecia na obscuridade e controvérsia, passando a ser um diagnóstico de rotina na prática veterinária em geral. Os sinais clínicos são bem reconhecidos e as abordagens diagnósticas são bem desenvolvidas. Sabe-se que uma variedade de terapias tópicas e sistêmicas é eficaz, especialmente quando fatores predisponentes são identificados e corrigidos.